بسم الله الرحمن الرحیم

DENTAL ANOMALY

Dr samaneh hemmati

Classification

- **Anomalies of Number**
- **Anomalies of Size**
- **Anomalies of Shape**
- **Anomalies of Structure**
- **Anomalies of Color**

- Initiation
- Proliferation
- Morphodifferentiation
- Histodifferentiation
- Apposition
- calcification

Anomalies of Number

1. Anodontia: a complete absence of one or both dentition.
2. Hypodontia (partial anodontia): a deficiency in tooth number.
3. Hyperdontia (Supernumerary Teeth): an excess in tooth number.
   a. Mesiodens b. Distomolar

Supernumerary Teeth (hyperdontia, supplemental teeth)

* 3% , familial tendency
  * Mesiodens
  * Single : premaxilla, maxillary molar
  * Multiple : premolar area, mandibular
* M : F = 2 : 1
* Impaction or delay eruption of normal teeth; dentigerous cyst
* Supplemental or rudimentry

DISTODENS

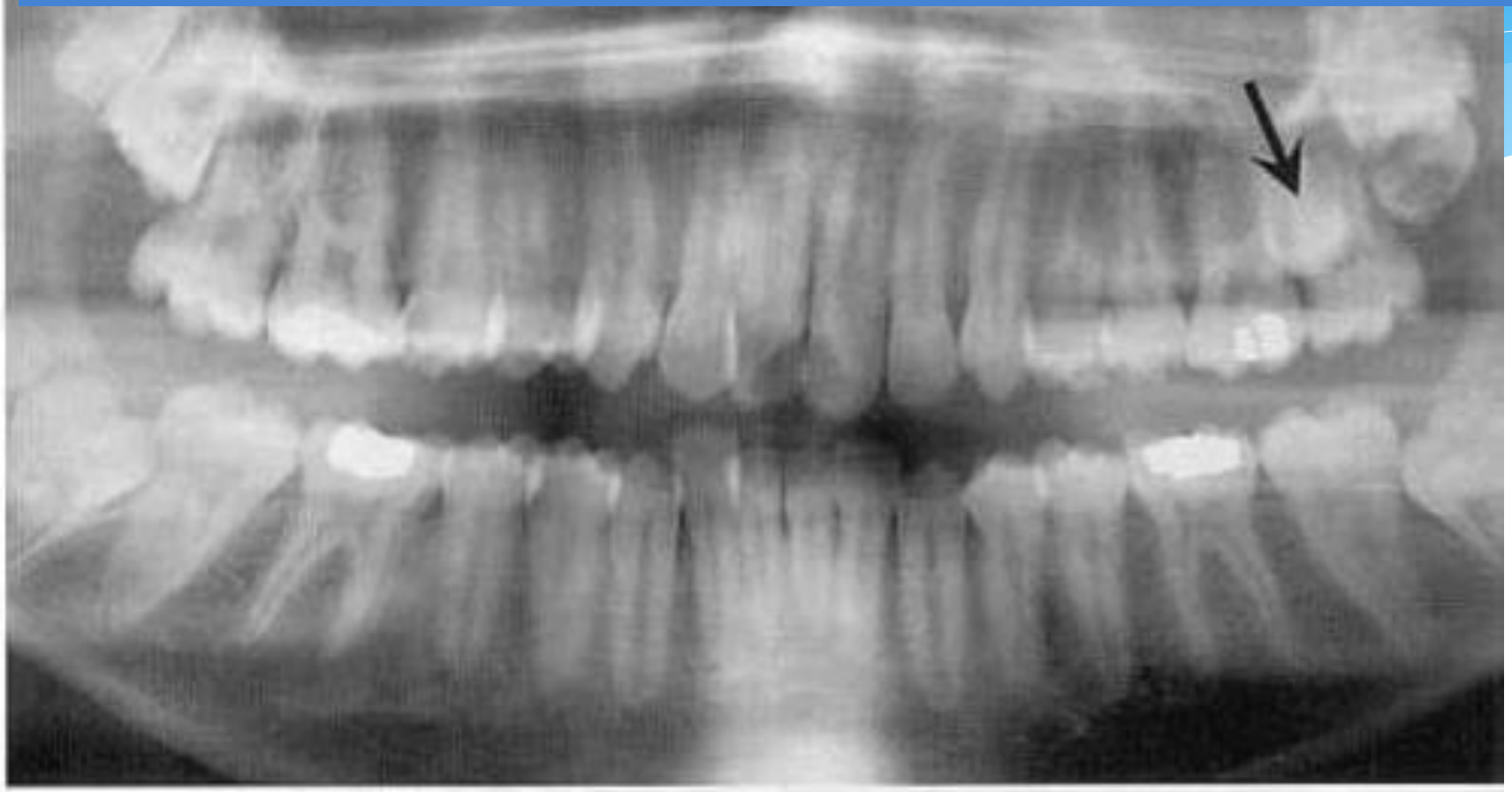

FIG. **18-2** In this panoramic image distomolars or fourth molars can be seen in both maxillary quadrants as well as a supplemental molar in the left maxilla, bringing the total to five molars in this quadrant.

PARATEETH

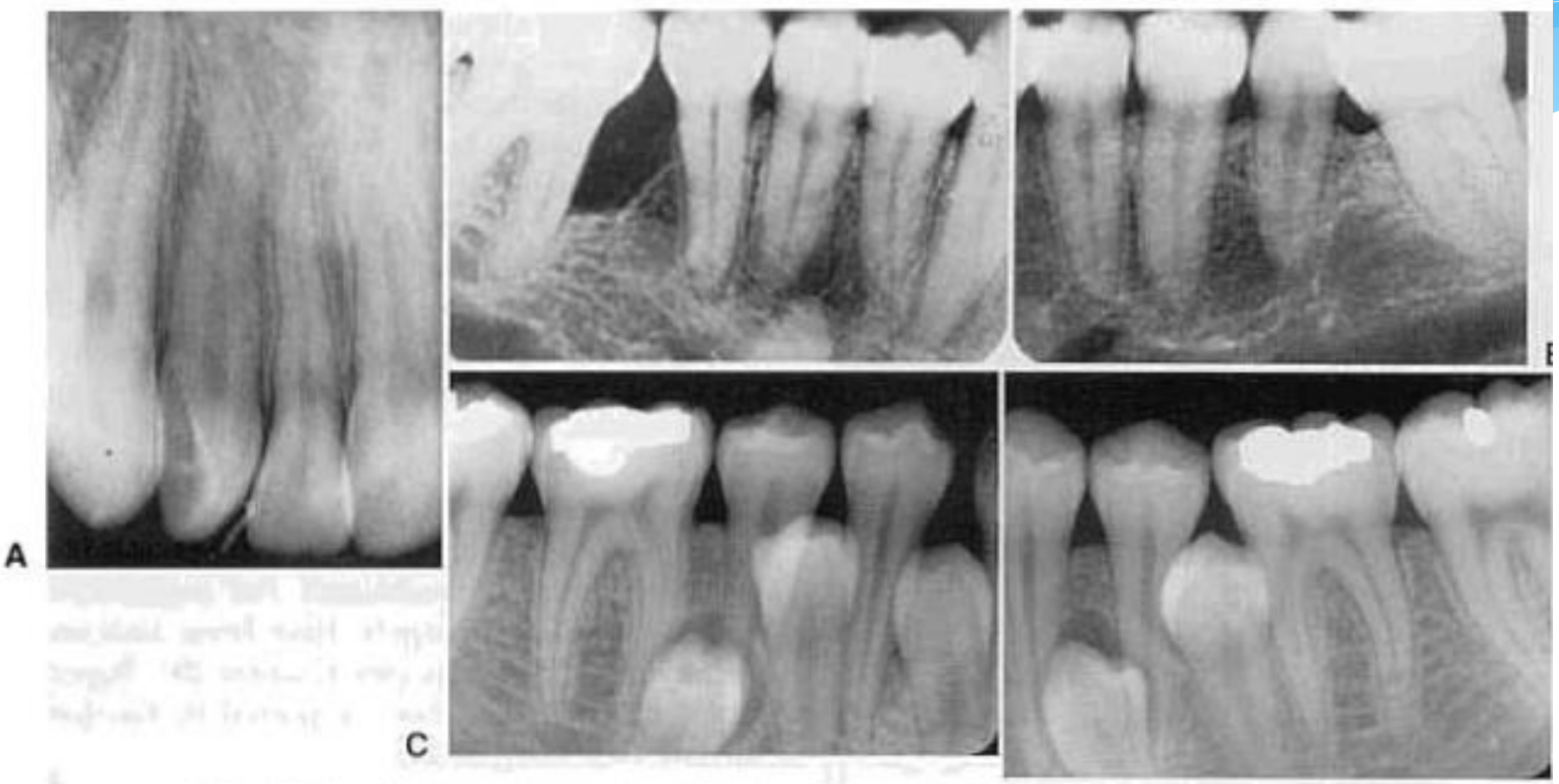

FIG. **18-3** Supernumerary or supplemental lateral incisors, **A**, and premolars, **B** and **C**.

Syndromes with supernumeraries

* ***Cleidocranial dysplasia*** *(cleidocranial dysostosis)*
* ***Gardner's syndrome***

Cleidocranial Dysplasia

* Mendelian dominant inheritance from either parent.
* Brachycephaly; delayed closure of fontanelles; wormian bones.
* Hypoplasia or aplasia of clavicles.
* Multiple supernumerary teeth.

Cleidocranial dysplasia: Panoramic radiograph of same Patient multiple supplemental supernumerary premolars.

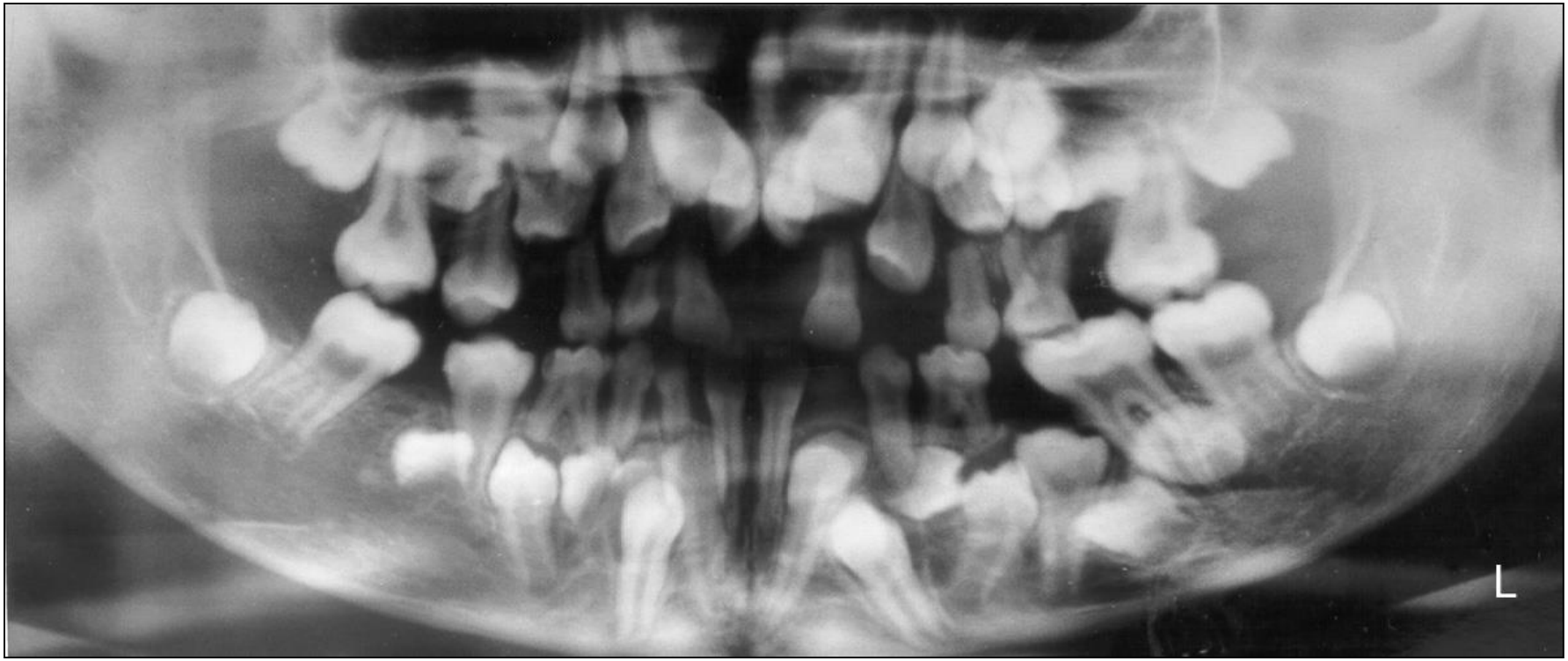

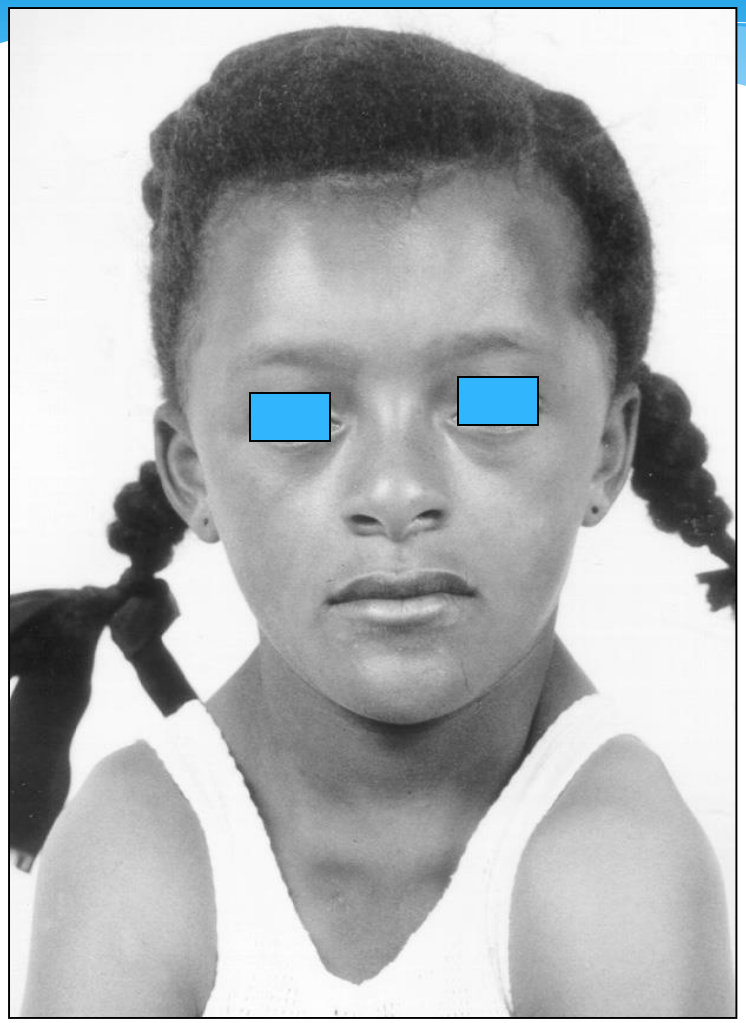

Cleidocranial dysplasia: clavicles are aplastic or entirely absent.

Gardner's Syndrome

* Autosomal dominant inheritance.
* Multiple polyposis of large intestine (cancer potential).
* Osteomas of long bones, skull and jaws.
* Multiple epidermoid or sebaceous cysts.
* Impacted supernumerary and permanent teeth.

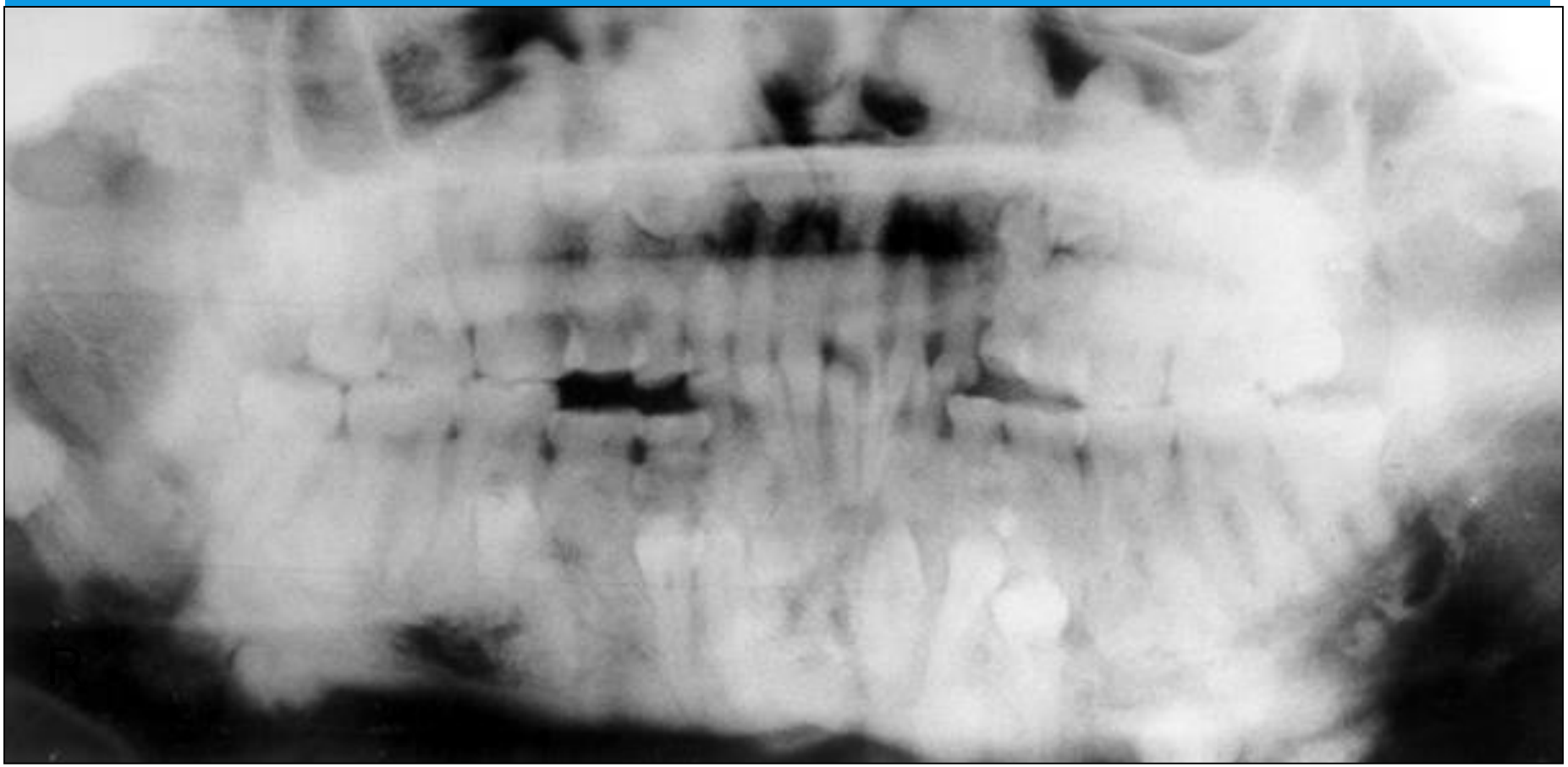

Gardner’s syndrome: note multiple osteomas in both jaws, retained primary teeth and multiple impacted permanent teeth. Such patients also are prone to intestinal polyposis.

Missing Teeth

* 1/5~10%, excluding 3rd molars
* Hypodontia
* Oligodontia
* Anodontia
* **Males and females are equally affected**
* 8 > 5 > 2
* *Ectodermal dysplasia*

HYPODONTIA

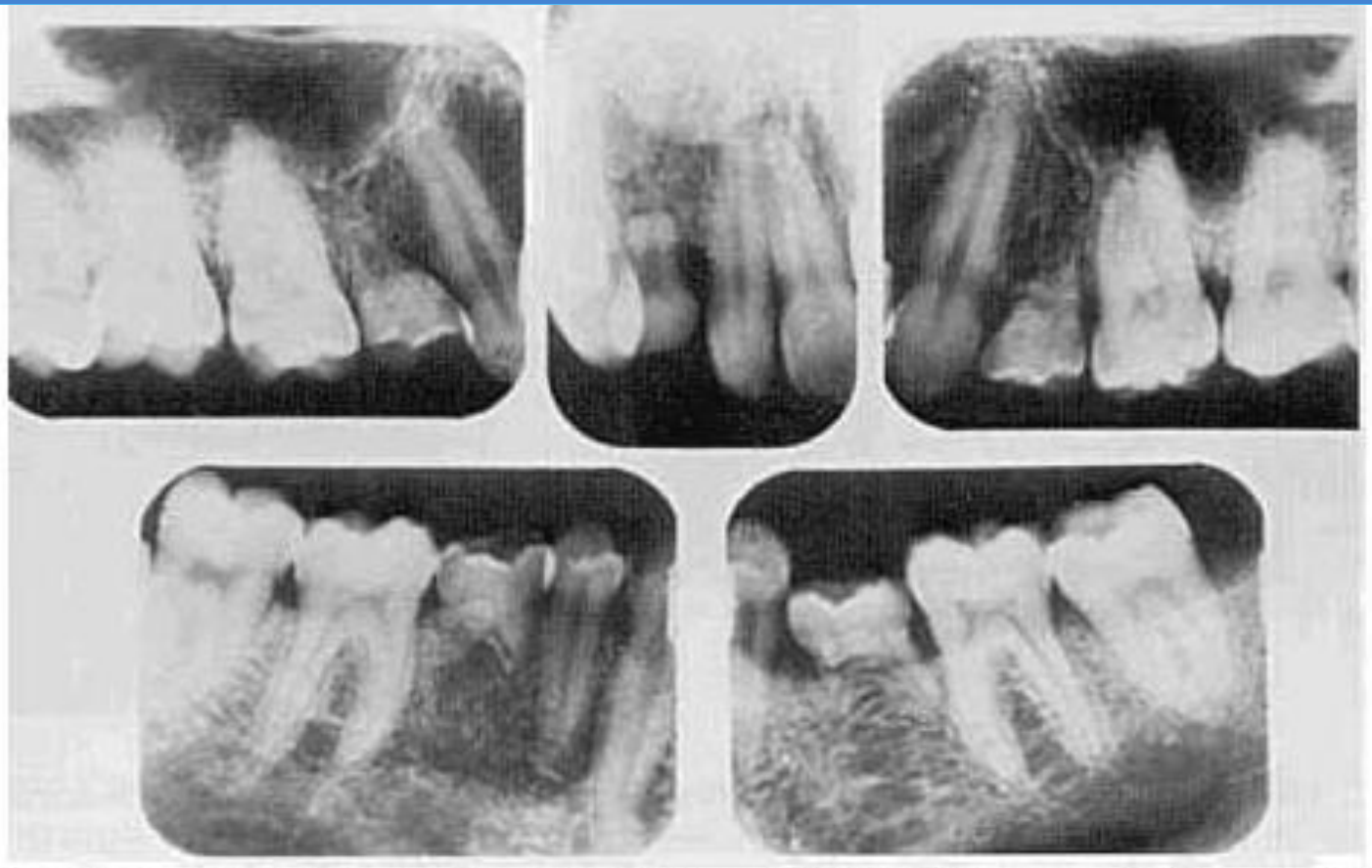

FIG. **18-6** Developmental absence of all maxillary premolars and both mandibular second premolars. Note the retention of the maxillary primary canine as a result of the posterior position of the maxillary permanent canine.

ECTODERMAL DYSPLASIA

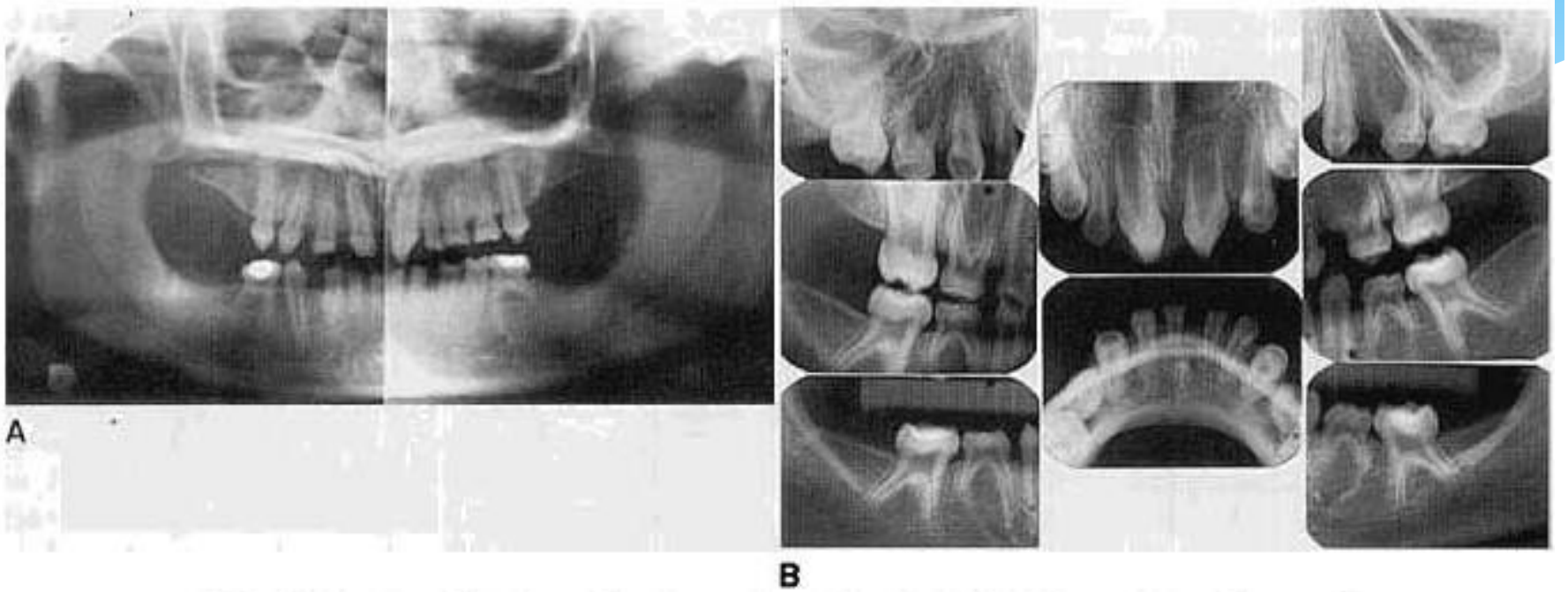

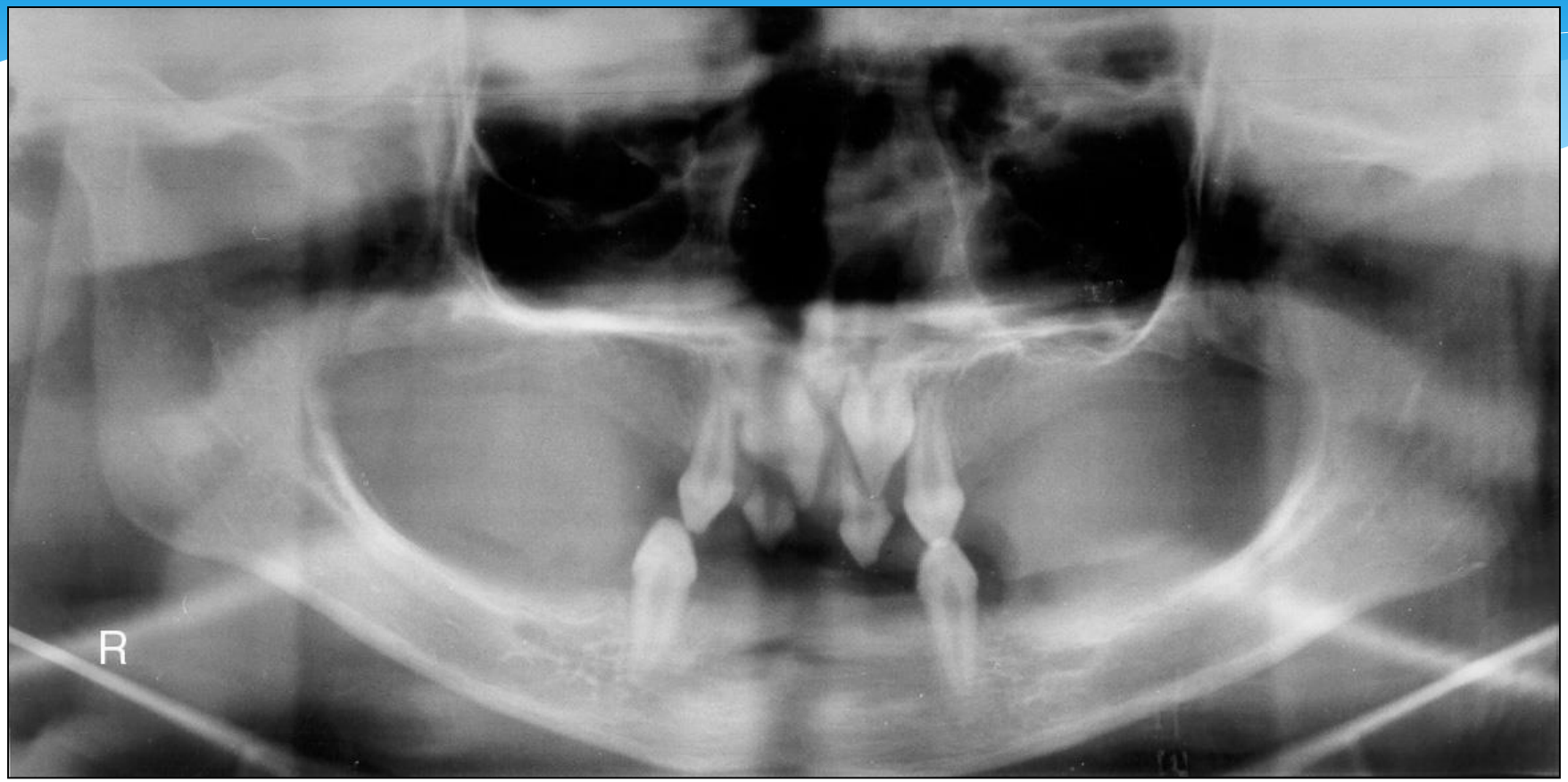

Ectodermal dysplasia: note severe oligodontia and conical teeth.

Hypodontia
Oligodontia
“Partial Anodontia”

missing
lateral incisor

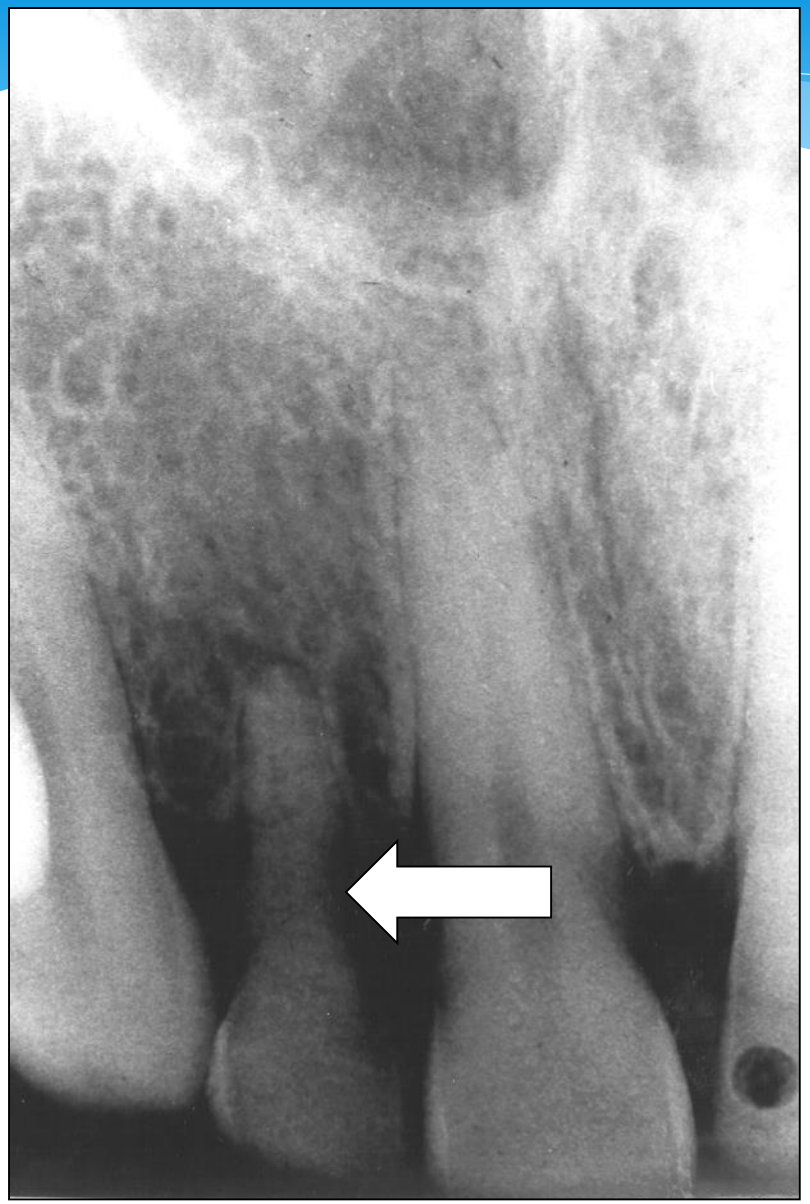

Oligodontia (hypodontia) with retention of primary lateral incisor tooth.

Hypodontia with retained primary second molar tooth. Note periodontal destruction around adjacent permanent teeth.

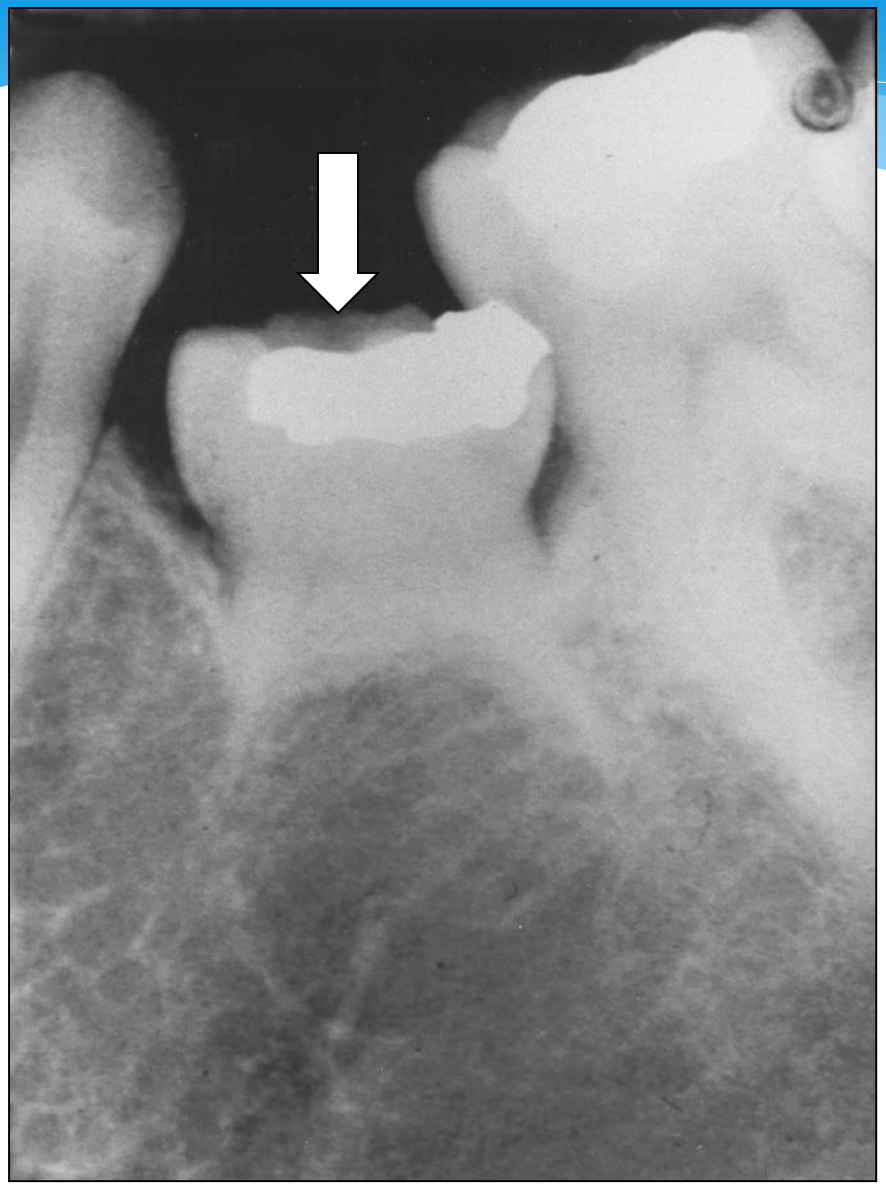

Hypodontia with ankylosed primary second molar tooth.

SIZE OF TEETH

* True generalized type and relative type

Macrodontia

* Hemangioma, hemihypertrophy of the face, pituitary giantism

Microdontia

* pituitary dwarfism
* supernumerary teeth, 3rd molars, lateral incisors
* **morphodifferentiation**

Microdont (“peg”) maxillary left lateral incisor.

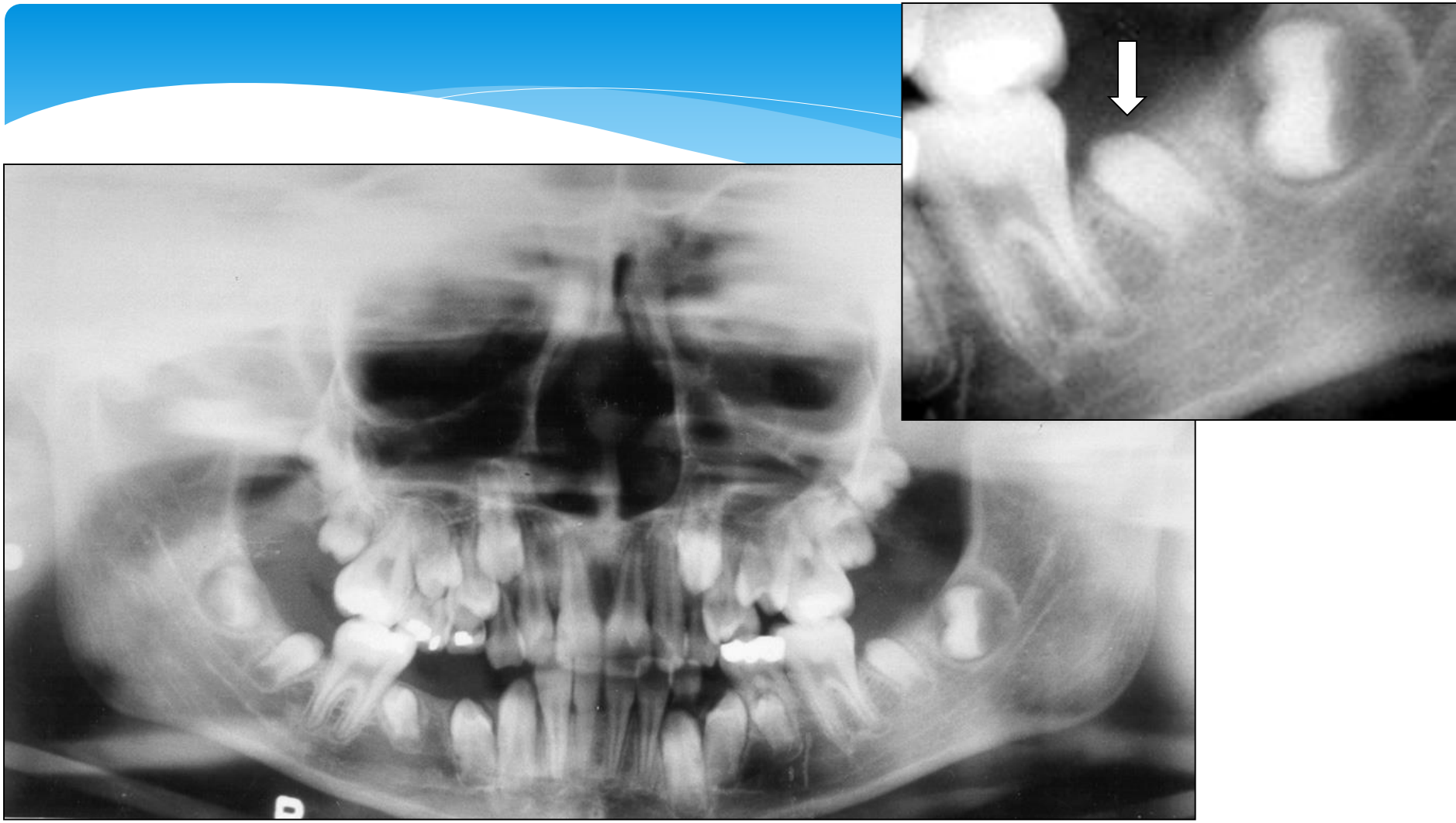

Multiple microdonts (small teeth): note size of mandibular second molar teeth

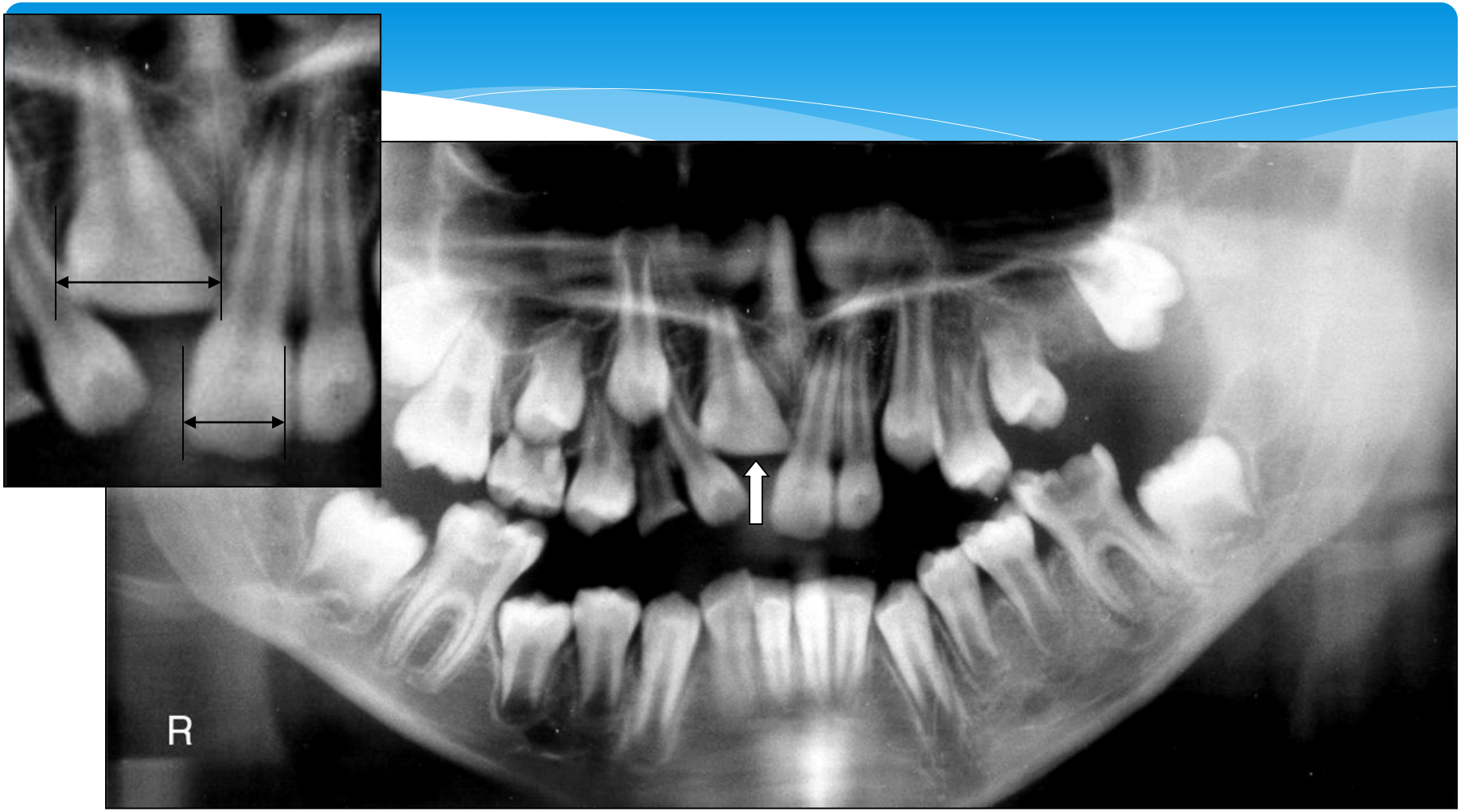

Macrodontia (large tooth) of right maxillary permanent central incisor tooth. Compare the mesio-distal dimensions to the normal left central.

Macrodont right maxillary central incisor (possibly due to fusion to supernumerary).

Detail from panoramic radiograph: macrodont mandibular third molar tooth.

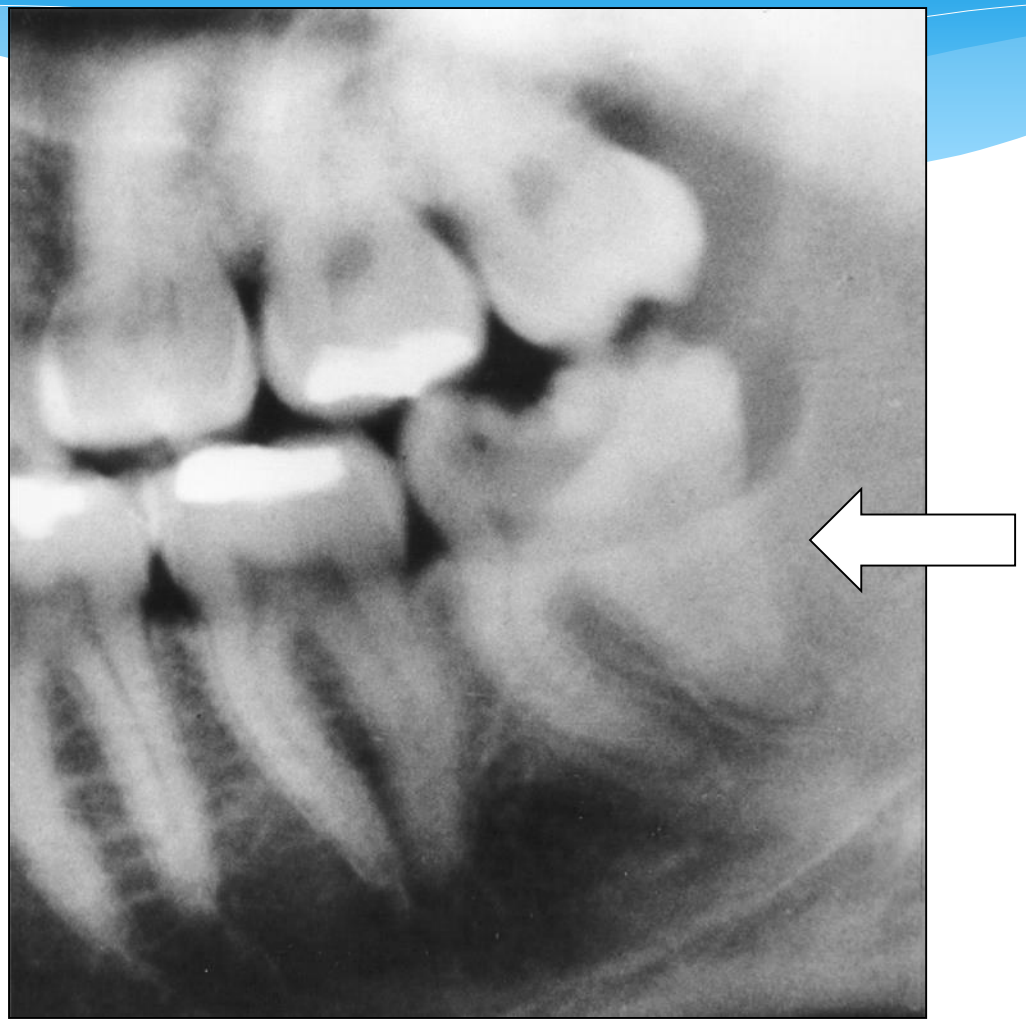

Anomalies of Shape

1. Gemination
2. Fusion
3. Concrescence
4. Dilaceration
5. Enamel Pearl (enameloma)
6. Talon Cusp
7. Taurodontism
8. Dens in Dente (dens invaginatus)
9. Dens Evaginatus
10. Supernumerary Roots
11. Hypercementosis

Gemination (twinning)

* 0/5%, The partial development of two teeth from a single tooth bud following incomplete division.

* An incomplete division of a single tooth bud resulting in a bifid crown with a single pulp chamber.
* more common in the primary dentition, esp. anterior region

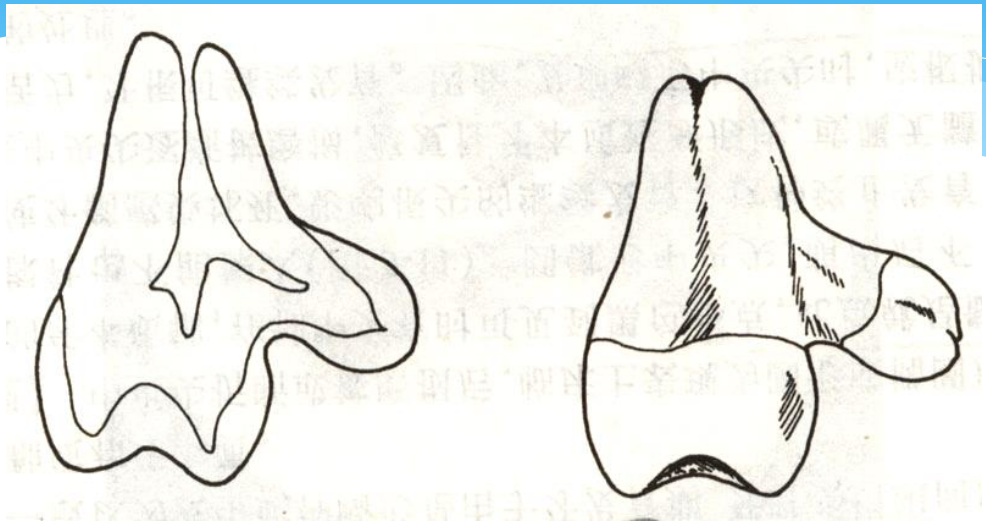

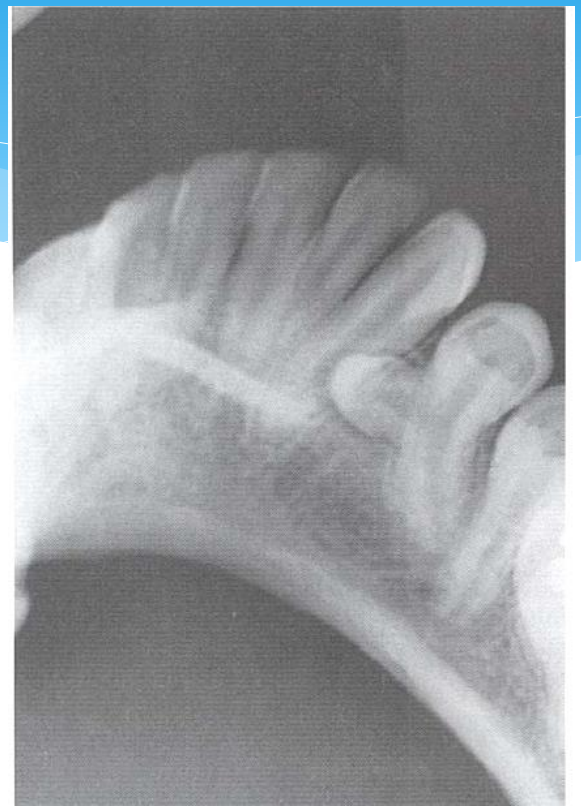

Geminated teeth

Fusion (synodontia)

-0/5%, Adjacent tooth germs combined with dentin or enamel

* bifid crown or two recognizable teeth, reduced number of teeth
* more common in the primary dentition, esp. anterior region

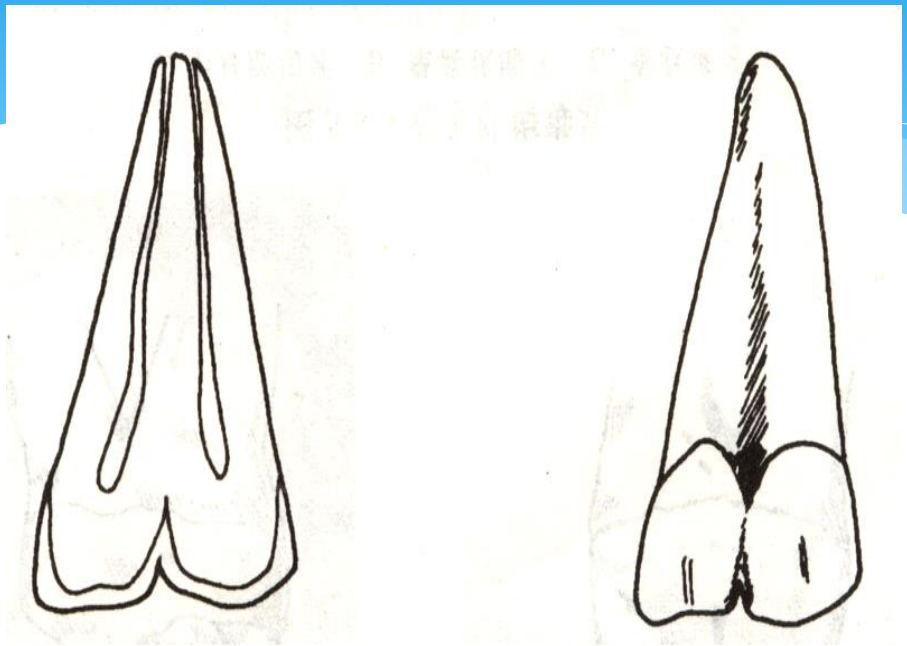

Fused teeth

Concresence

- Roots of two or more teeth united by cementum

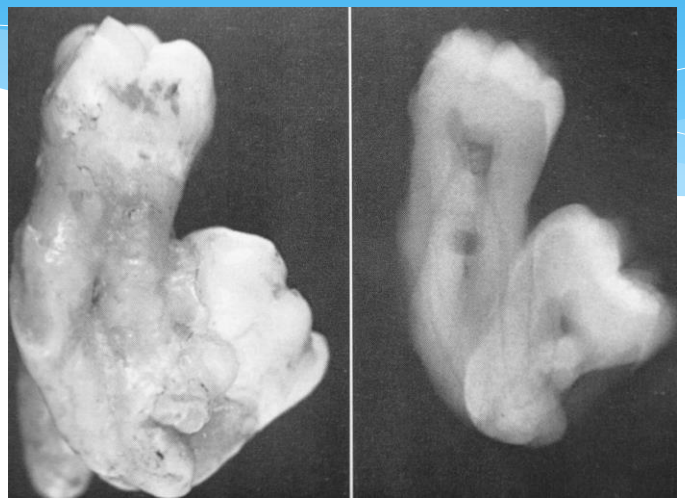

* space restriction during develop., local trauma, excessive occlusal force or local infection after development
* maxillary molars; 3rd molar & a supernumerary tooth

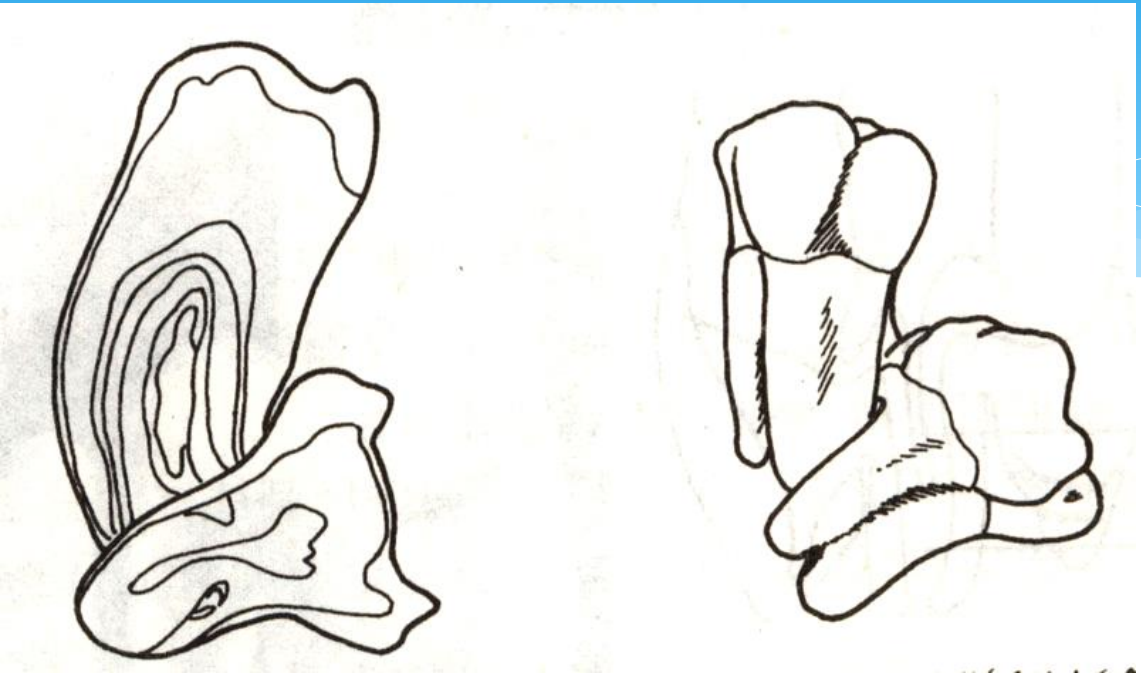

Concrescence of teeth

Concrescence

Fusion / Gemination

* A tooth with two separated root canals and with one or two roots…Fusion
* An enlarged tooth with a bifid crown containing an enlarged or possibly partially divided pulp chamber…Gemination

GEMINATION	FUSION	CONCRESCENCE
One bud	Two buds	Two buds
One tooth	one teeth	Two teeth
One canal	Dentin union	Cementum union

Taurodontism

-0/5- 5%, Longitudinal enlarged pulp chamber, increased distance between CEJ to the bifurcation

- normal crown size & tooth length, shortened roots
- not recognizable clinically
- most in molars
- Trisomy 21

Dilaceration

- *0/3%, A sharp bend or curve in the crown or root*

* maxillary premolars

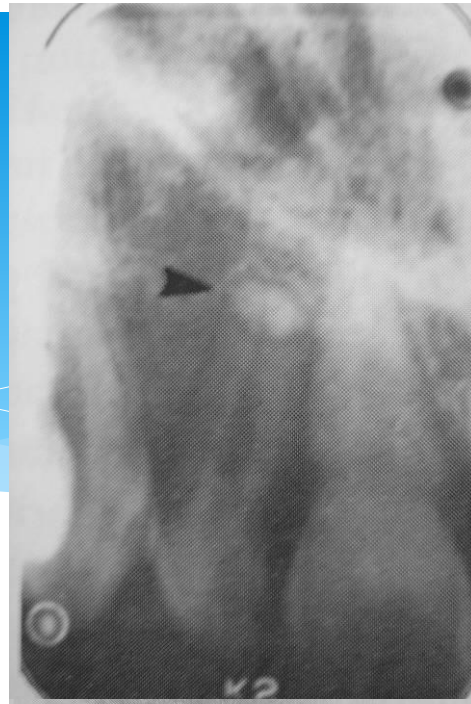

DILACERATION

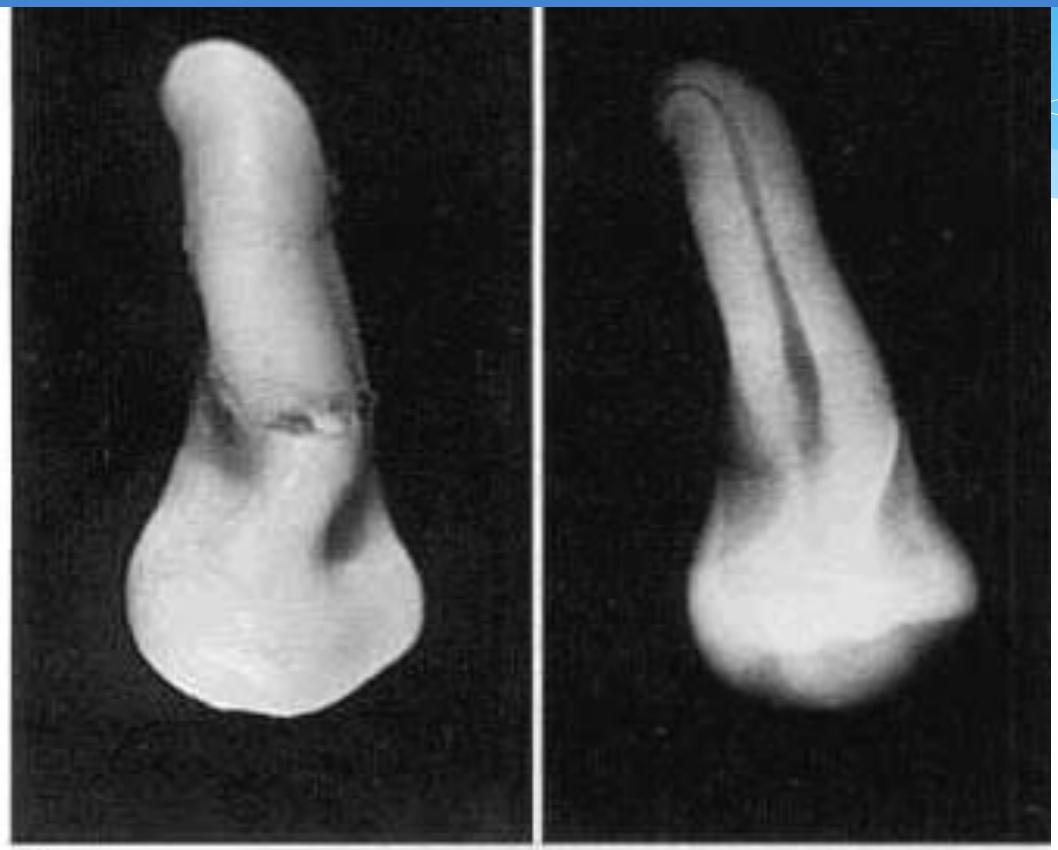

A B

FIG. **18-16** **A**, Dilaceration of the crown may be readily recognized clinically. **B**, Radiograph of the specimen in **A** (Courtesy Dr. R. Kienholz, Dallas, Texas.)

Dens in Dente (dens invaginatus)

- *10%, Infolding of the outer enamel surface into the interior*

* at the anatomically defined pit
* caries→pulpal disease


DENTAL ANOMALIES

Dens Evaginatus

- Outfolding of enamel organ

* a tubercle on occlusal surface, with enamel surface & dentin core, pulp horn often extends into the evagination
* premolar or molar
* pulp infection due to fracture

Talon Cusp

- *Anomalous hyperplasia of the cingulum of a Max. or Mand. incisor →a supernumerary cusp*

* T shaped in incisal view
* Differential diagnosed with supernumerary tooth

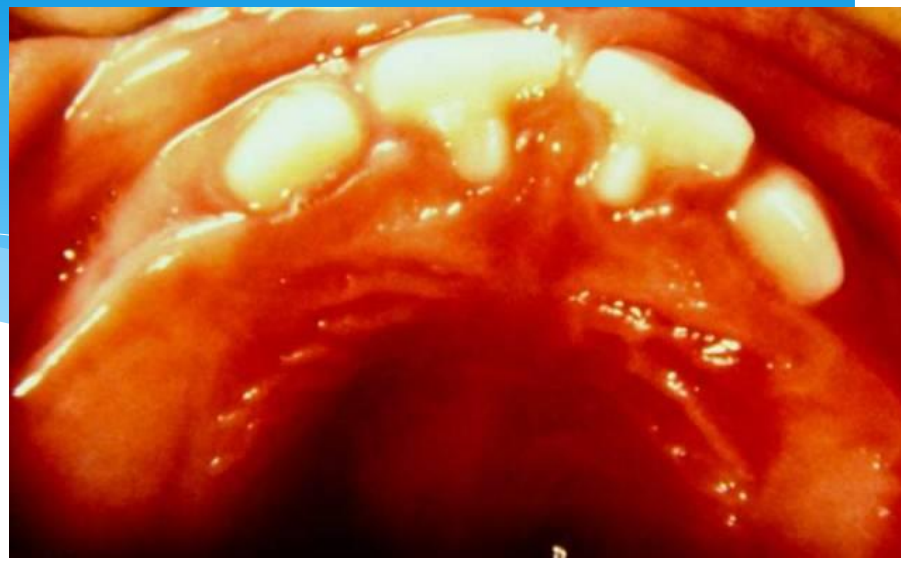

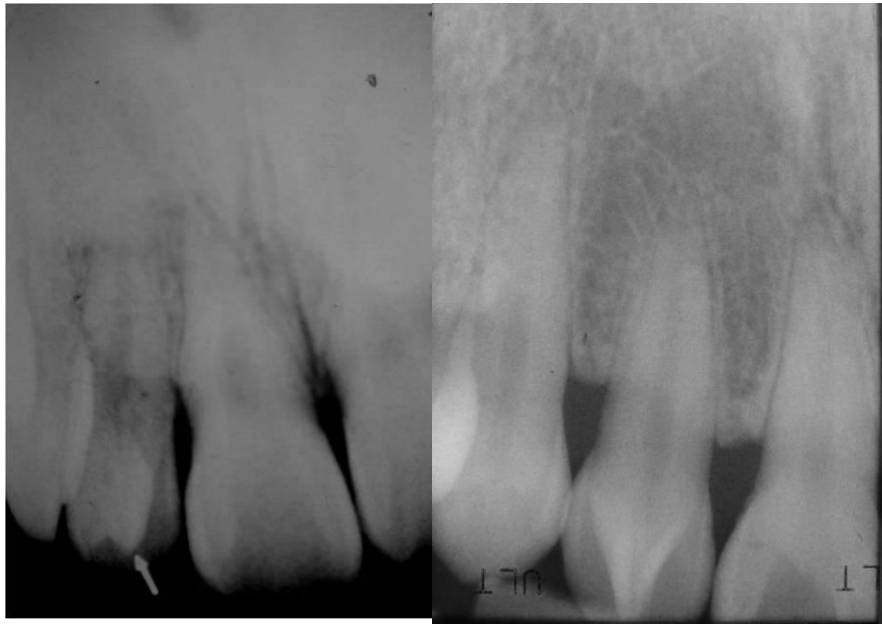

DENS EVAGINATUS

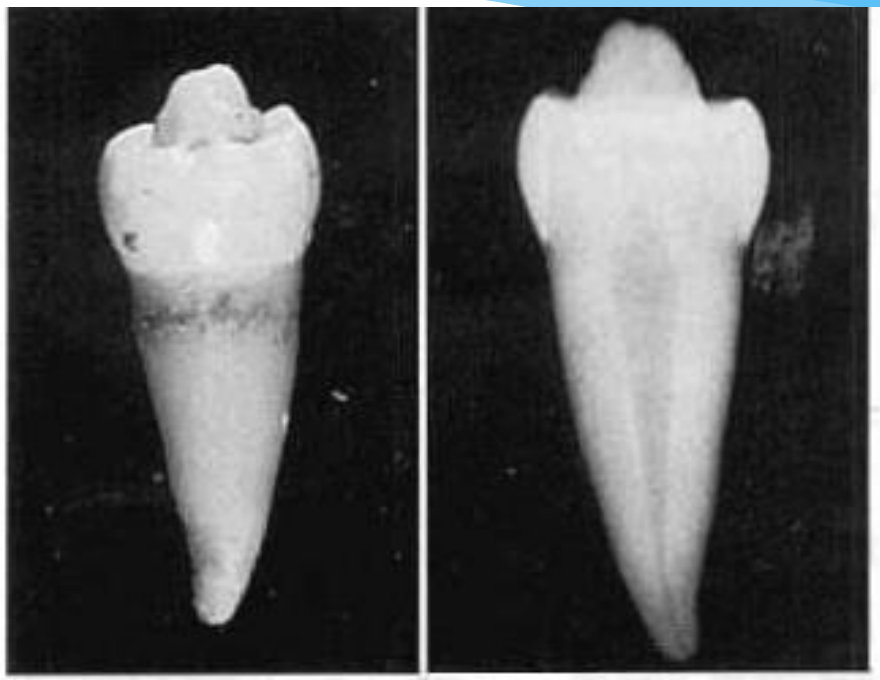

A B

FIG. **18-23** A, Dens evaginatus, seen as a tubercle in the mandibular premolar. B, Radiograph of the specimen. (Courtesy Dr. R. Kienholz, Dallas, Texas.)

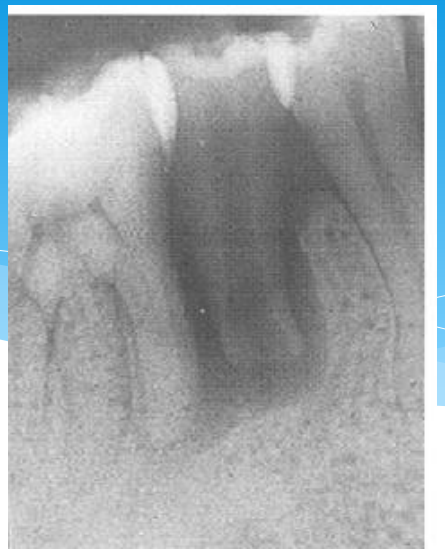

Dens evaginates

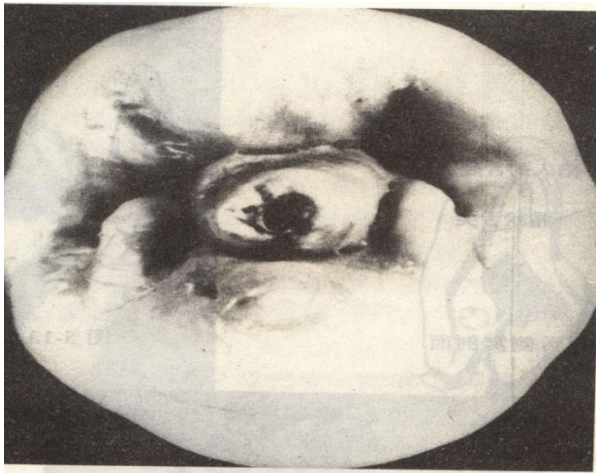

The treatment of abnormal central cusp

* Grinding
* Pulp capping
* Apexification
* Root canal therapy

Dens in dente (dens invaginatus) of maxillary right lateral incisor.

⇩ ***invagination (pulp side)***

⇧ ***invagination (cingulum)***

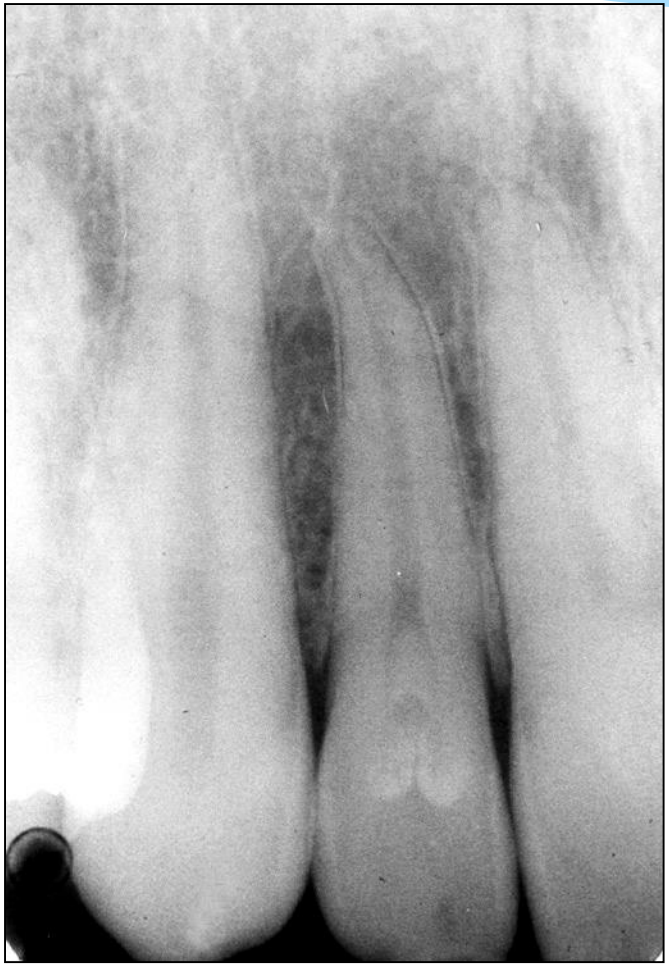

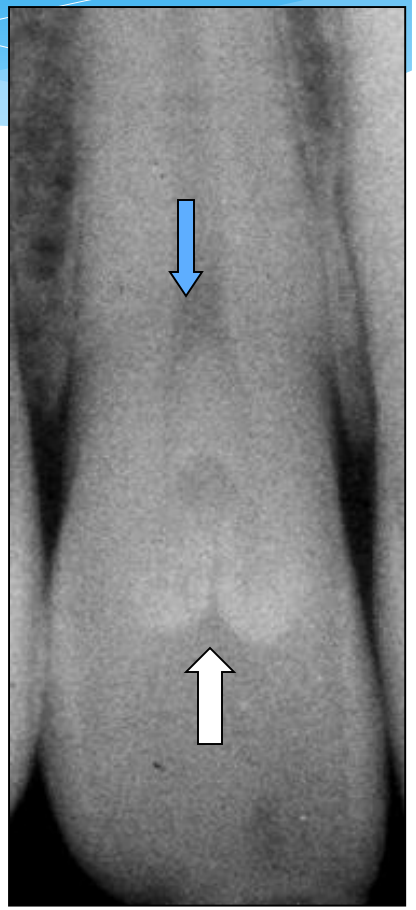

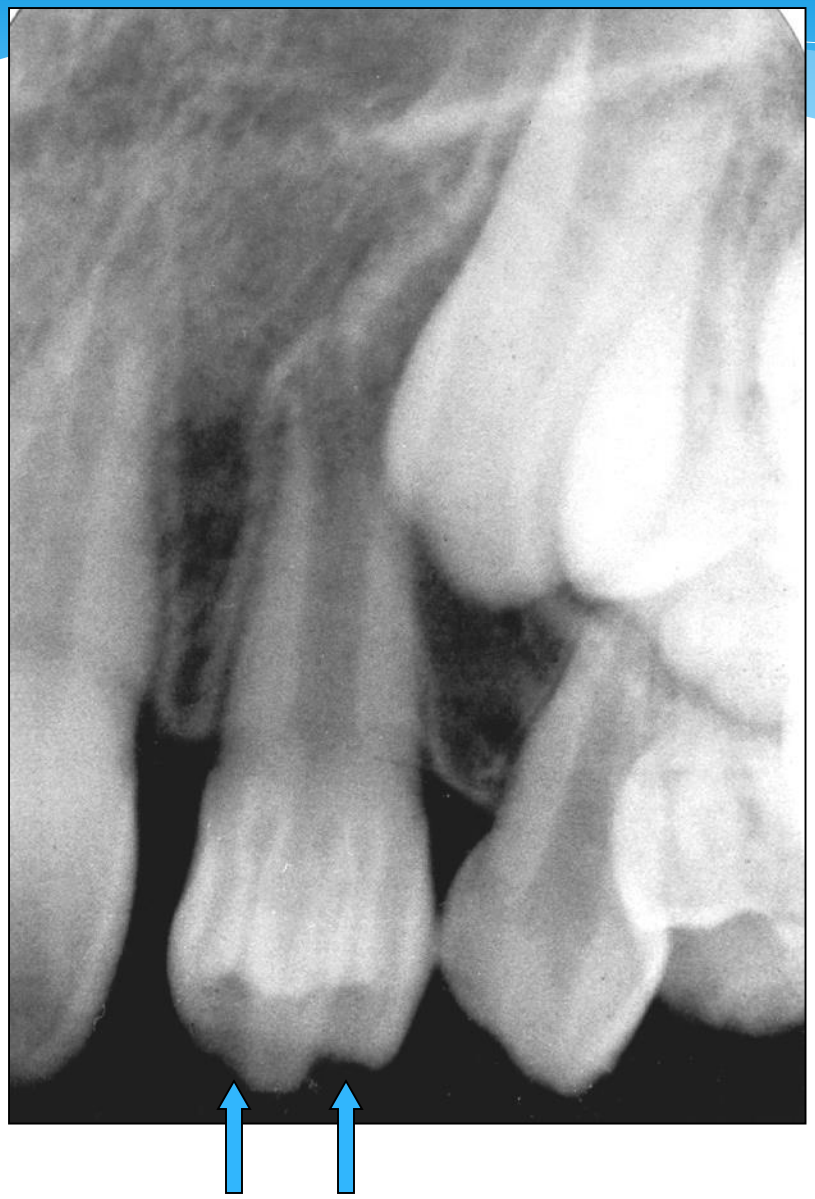

Double dens in dente of maxillary lateral incisor tooth.

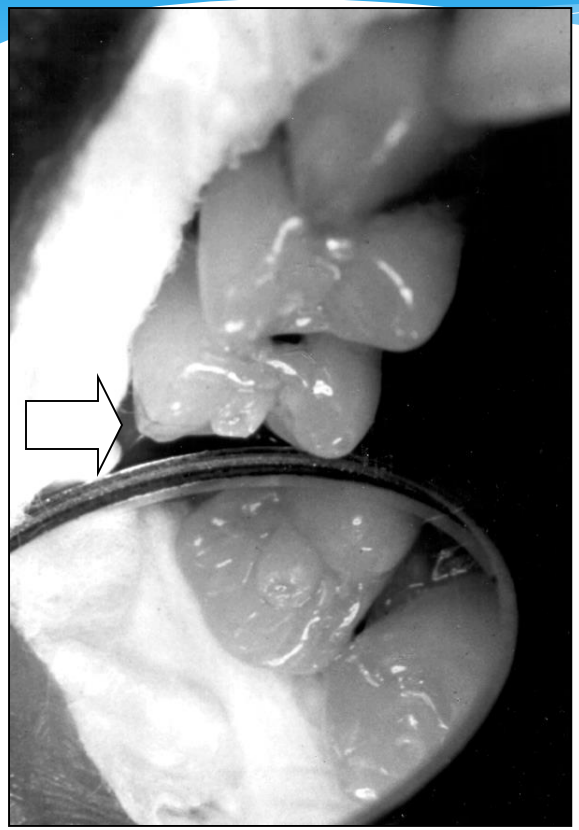

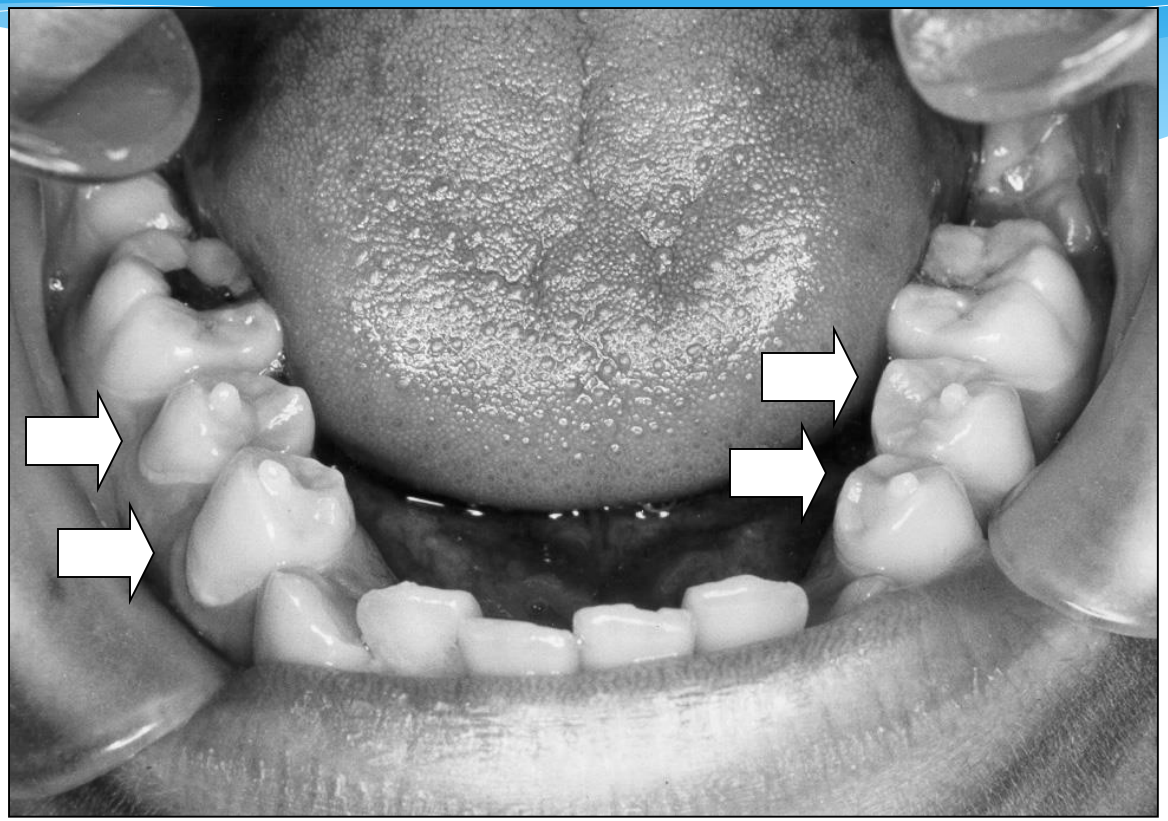

Dens evaginatus (tuberculated premolars; Leung's premolar).

Dens evaginatus (mandibular second premolar). Pulpal tissue often extends into the evagination complicating traditional restoration preparations.

Enamel Pearl

* Tiny globule of enamel at bifurcation or trifurcation of molar root.
* Found in about 2 % of maxillary molars and <0.5 % of mandibular molars.

Photograph ***Radiograph***

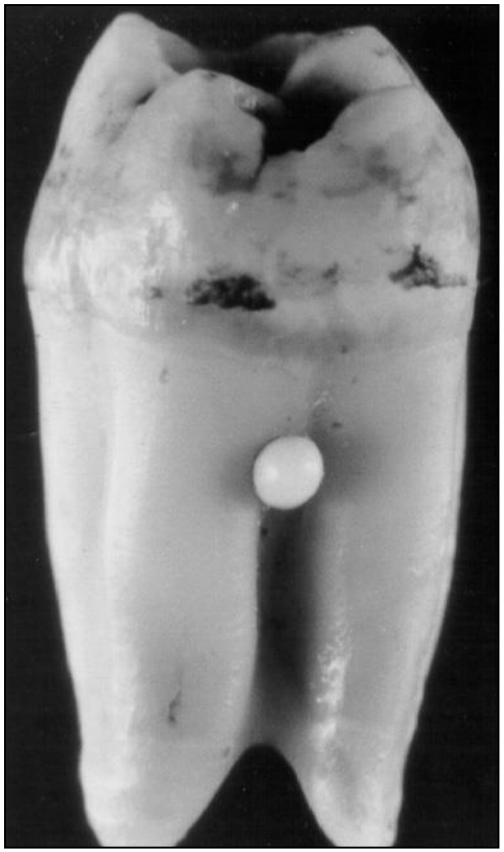

Enamel pearl on extracted molar tooth is situated at the furcation of the roots.

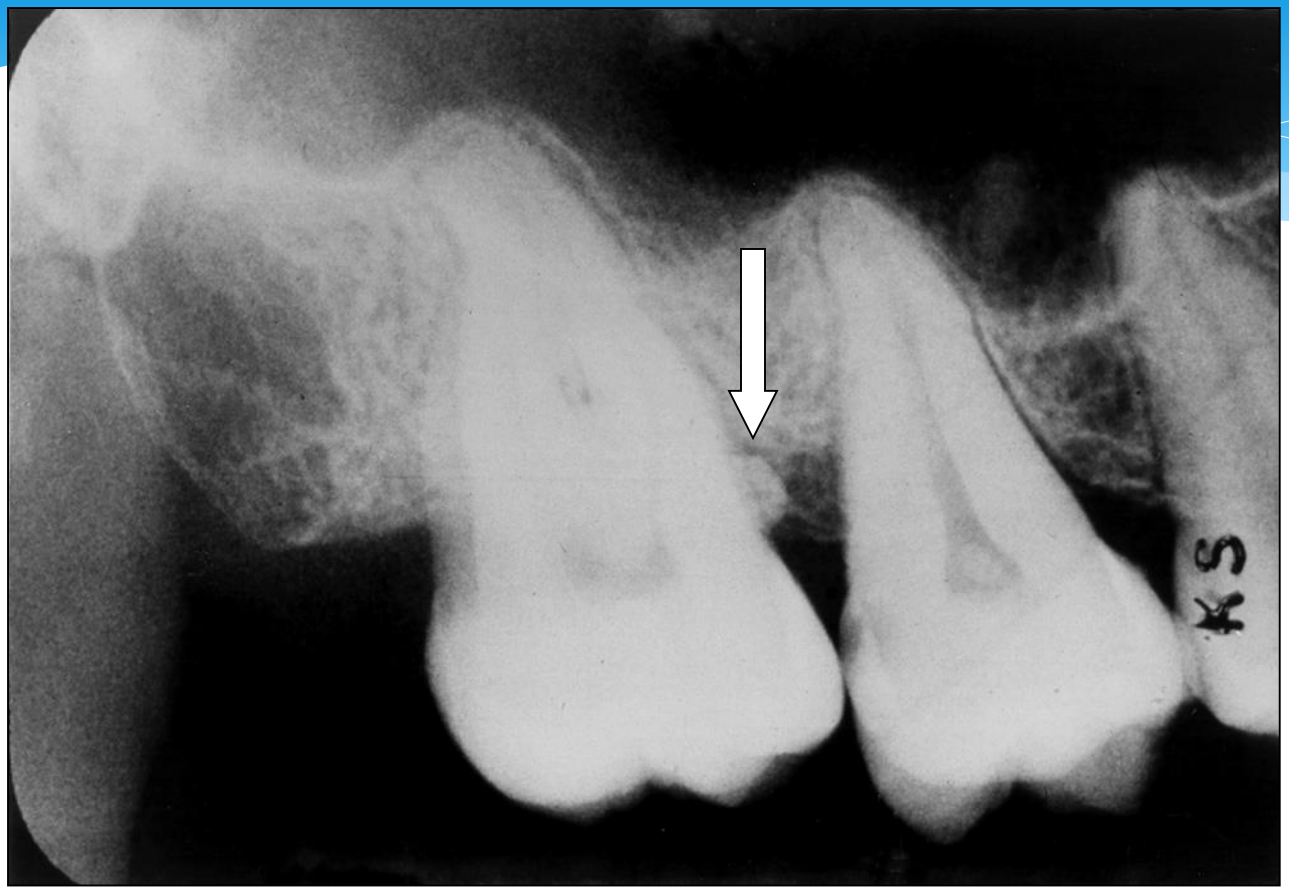

Enamel pearl on proximal surface of right maxillary first molar tooth.

Anomalies of Structure

1. Enamel hypoplasia caused by
   amelogenesis imperfecta (genetic)
2. Enamel Hypoplasia caused by
   febrile Illness or Vitamin Deficiency
3. Enamel hypoplasia resulting from
   local infection or Trauma
   a. Turner's Tooth
4. Enamel hypoplasia resulting from
   fluoride Ingestion (dental fluorosis)
   a. Mottling

Anomalies of Structure

5. **Enamel hypoplasia resulting from congenital syphilis (Treponema pallidum)**
   a. Hutchinson's incisors **b. Mulberry molars**
6. **Enamel hypoplasia resulting from birth injury, premature birth or idiopathic factors**
7. **Enamel hypocalcification**
8. **Dentinogenesis imperfecta**
9. **Dentin dysplasia**
10. **Regional Odontodysplasia (Ghost teeth)**

Amelogenesis Imperfecta

-Disturbance in enamel development

* Normal dentin & root
* autosomal dominant or recessive , X-linked
* Four general types

Amelogenesis Imperfecta

Classification of AI

Type I: hypoplastic

TypeII: hypomaturation

TypeIII: hypocalcified

TypeIV: hypomaturation-hypoplastic with taurodontism

1.Hypoplastic type

* Thin enamel with pitted, rough or smooth & glossy surface; yellowish to brown
* undersized, squared crown, lack of contact
* flat occlusal surface & low cusps, attrition

2.Hypomaturation

* normal thickness of enamel, but mottled surface; cloudy white, yellow or brown, opaque in color
* softer than normal
* same density as dentin

3.Hypocalcified type

* normal thickness of enamel, density less than dentin
* normal size & shape when erupt, abrade or fracture away rapidly
* permeability increase, darkened & stained

4.Hypomaturation-hypocalcified with taurodontism

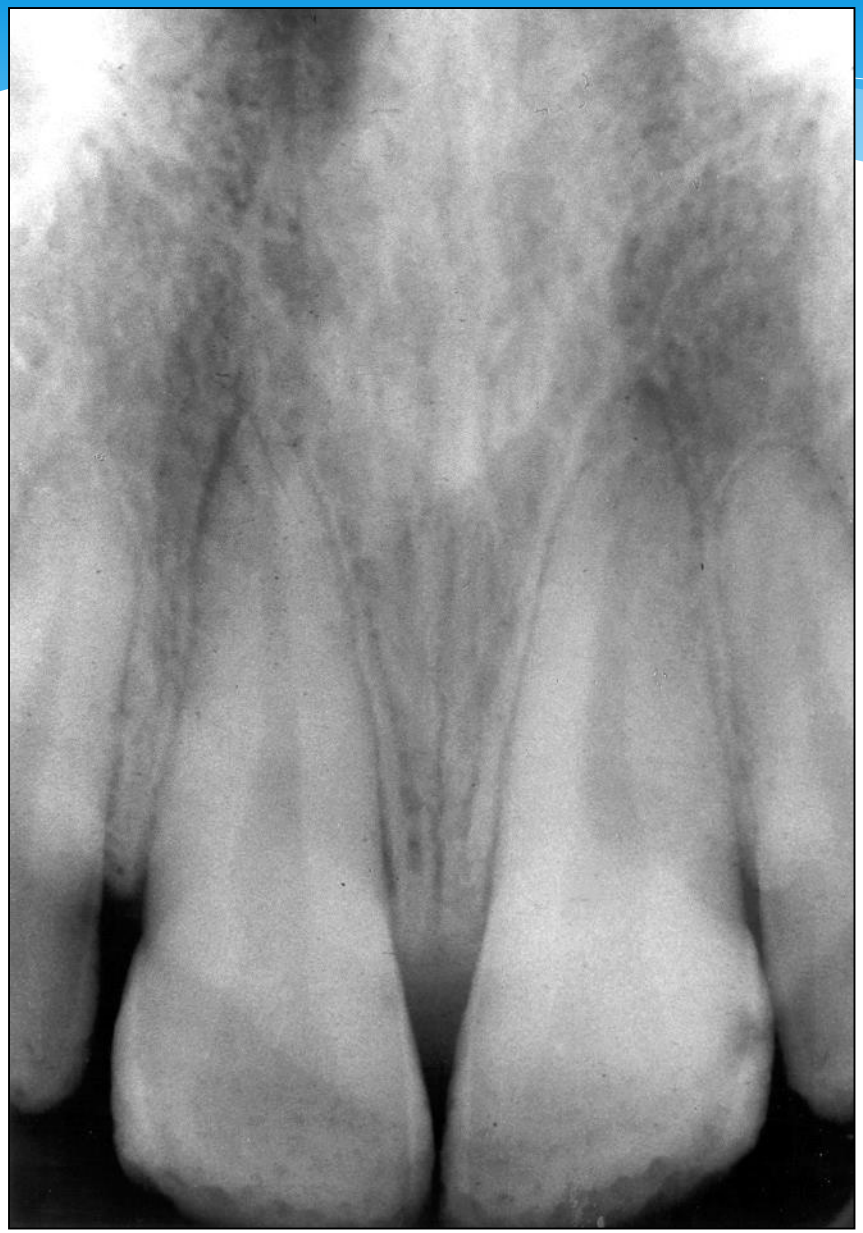

Hypomineralized amelogenesis imperfecta: Note “pitting” of enamel towards incisive edges of the centrals. The left central also has C3 dental caries of the distal proximal surface.

Amelogenesis Imperfecta

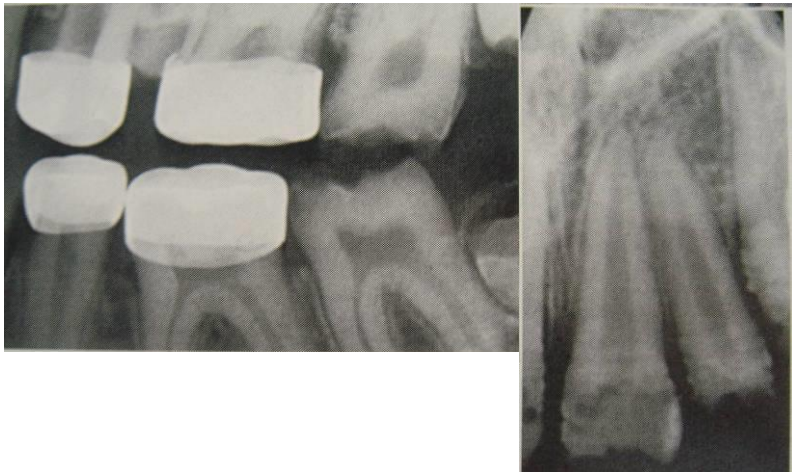

Inherited Dentin Structure

* Dentinogenesis imperfecta.
* Dentin dysplasia (Radicular vs Coronal).

Dentinogenesis Imperfecta

Classification of DI

Type I: occures with osteogenesis imperfecta

TypeII: hereditary opalescent dentin

TypeIII: Brandywine type

a shell-like appearance and multipe pulp exposures.

Dentinogenesis Imperfecta (hereditary opalescent dentin)

* autosomal dominant hereditary

  Type I : D.I. + osteogenesis imperfecta

  Type II : D.I., no skeletal defects
* enamel fractures, attrition severely
* dark brown to black

Remember

* **Most patients with dentinogenesis imperfecta DO NOT have osteogenesis imperfecta.**
* **ALL patients with osteogenesis imperfecta have dentinogenesis imperfecta.**

Dentinogenesis Imperfecta

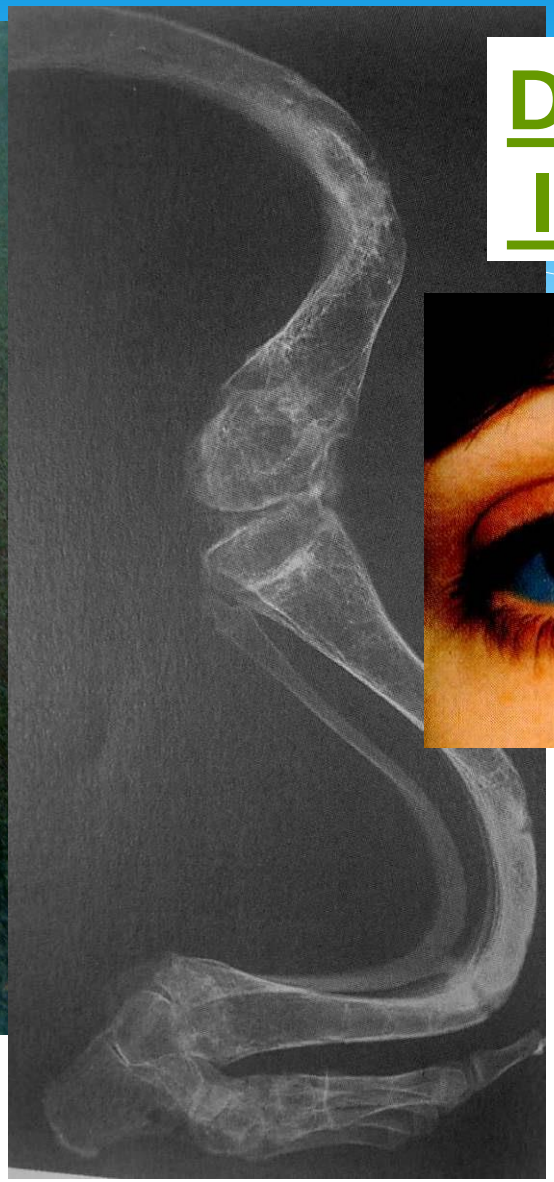

Osteogenesis imperfecta

Regional Odontodysplasia (odontogenesis imperfecta)

- *hypoplastic & hypocalcified of both dentin & enamel*

* only a few adjacent teeth in a quadrant affected either primary or permanent teeth
* central incisors > lateral incisors >canines (maxillary)
* delayed eruption
* ghostlike appearance in image
* large pulp chamber & wide root canals, roots are short & poorly outlined
* thin enamel , less dense as usual

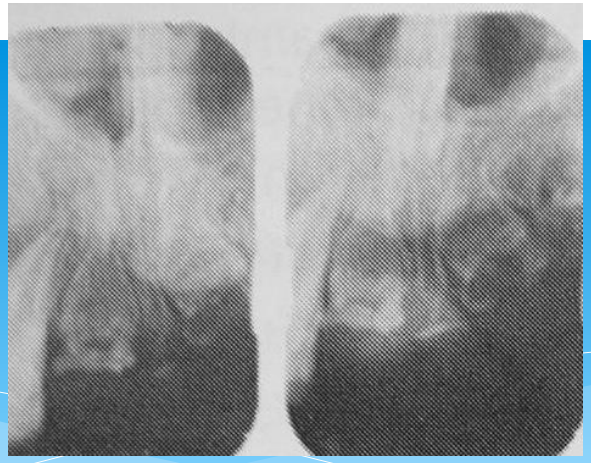

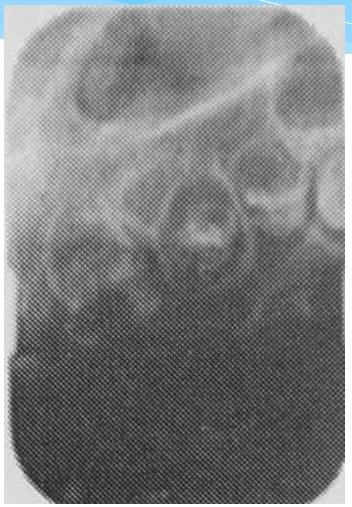

Regional Odontodysplasia

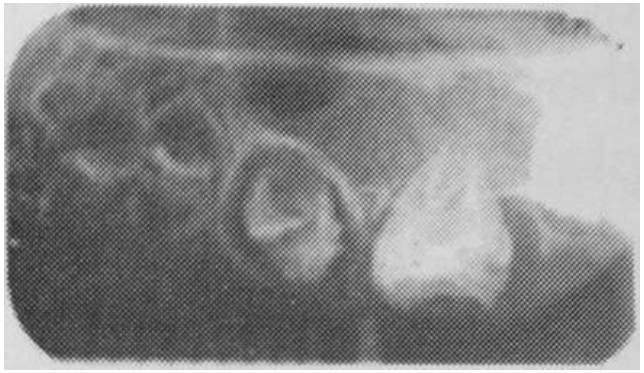

Impacted Teeth

* Diagnose : clinical examination or radiographs
* Etiology :
  * Overretained primary teeth
  * supernumerary teeth
  * severe crowding
  * Primary failure in the eruption
* the last tooth to erupt in an arch or quadrant is impacted

* most common : maxillary canine region
* Etiology :
  * longest distance to take its place in the arch
  * last tooth to erupt into the arch
* often erupt in a mesial direction
* Often impact palatally
* Diagnose : no bulge on the facial alveolus in the canine area at approximately 9 or10 Y/O

* Posterior tooth impaction result of inadequate arch length
  * tooth-jaw size discrepancy
  * premature primary tooth loss


با تشکر از توجه شما