DIABETIC FOOT

CHARCOT ARTHROPATHY

TREATMENT

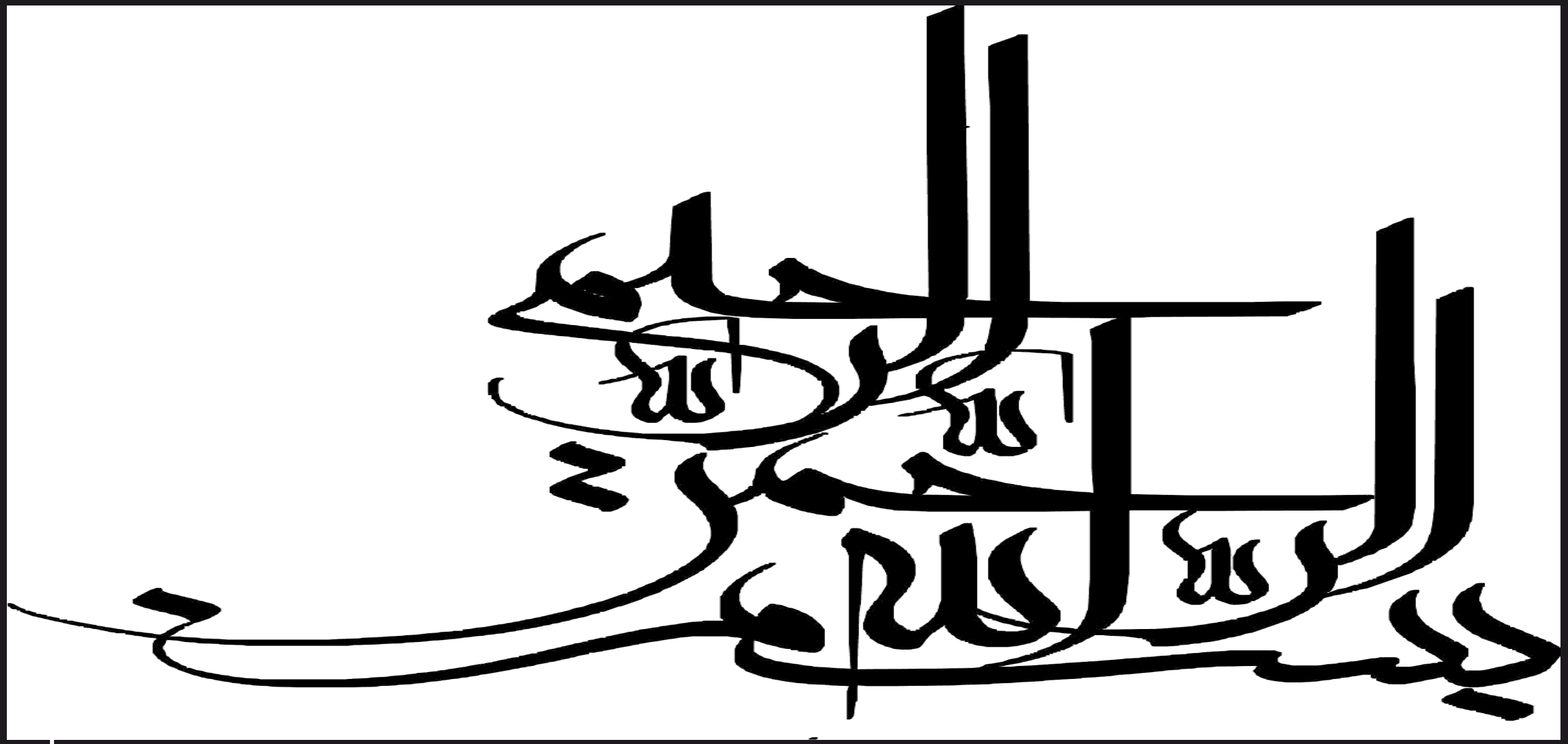
بسم الله الرحمن الرحيم

CHARCOT ARTHROPATHY

tibiotalocalcaneal arthrodesis with intramedullary nail

tibiotalocalcaneal arthrodesis with External Fixator

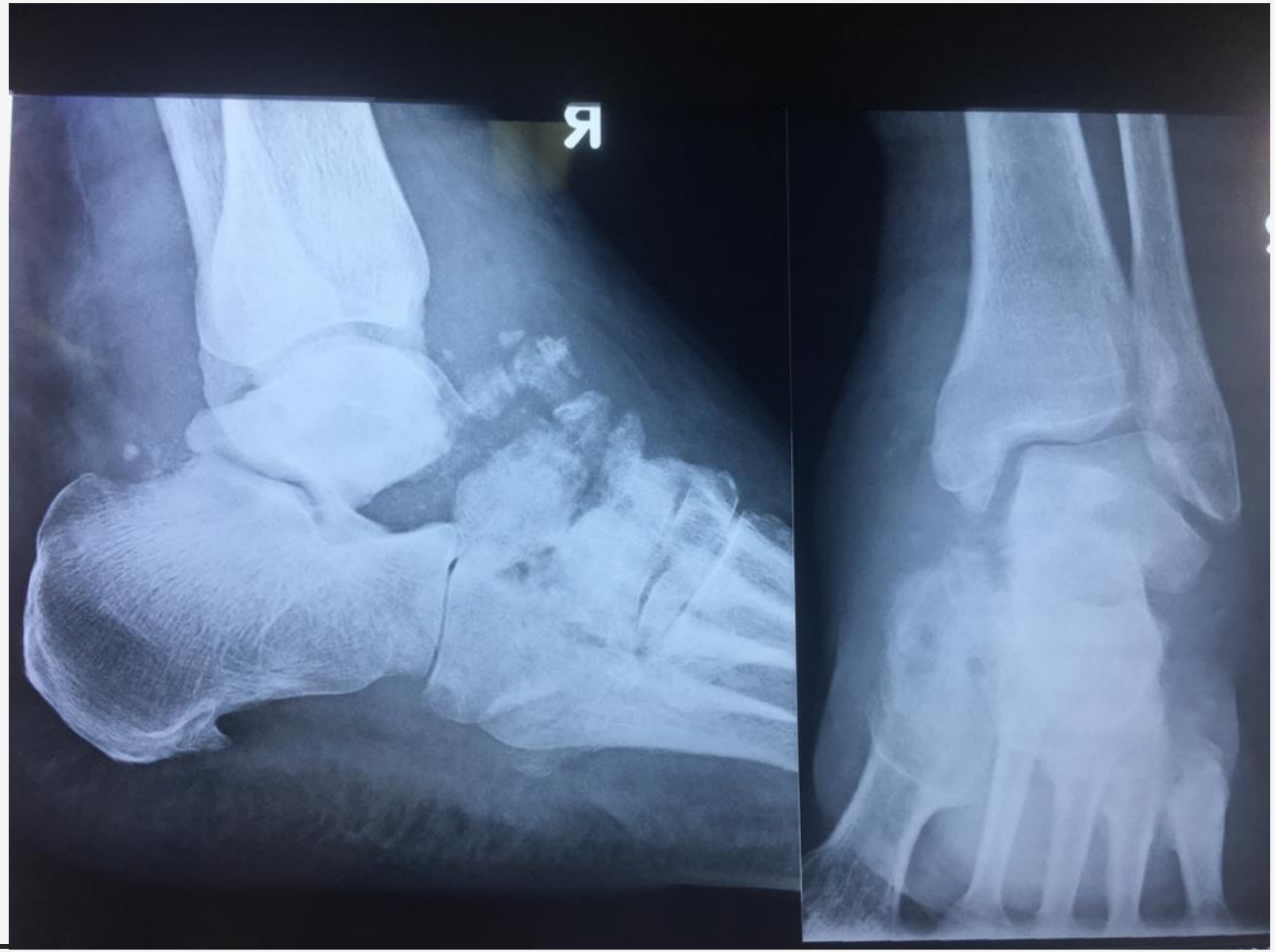
Я

20
22
24
26

Fluoro
85 KVP
1.4 mA
Chameleon

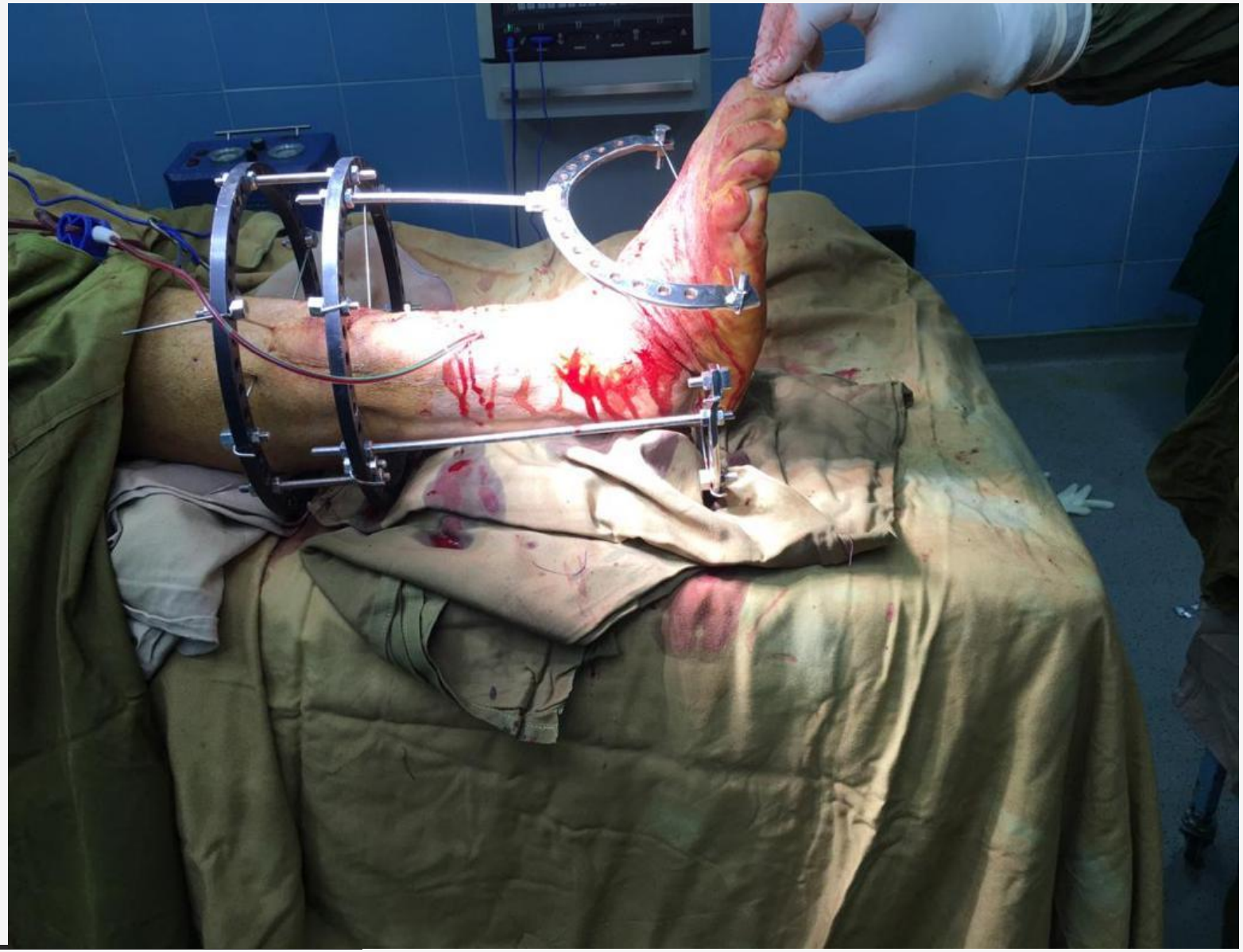

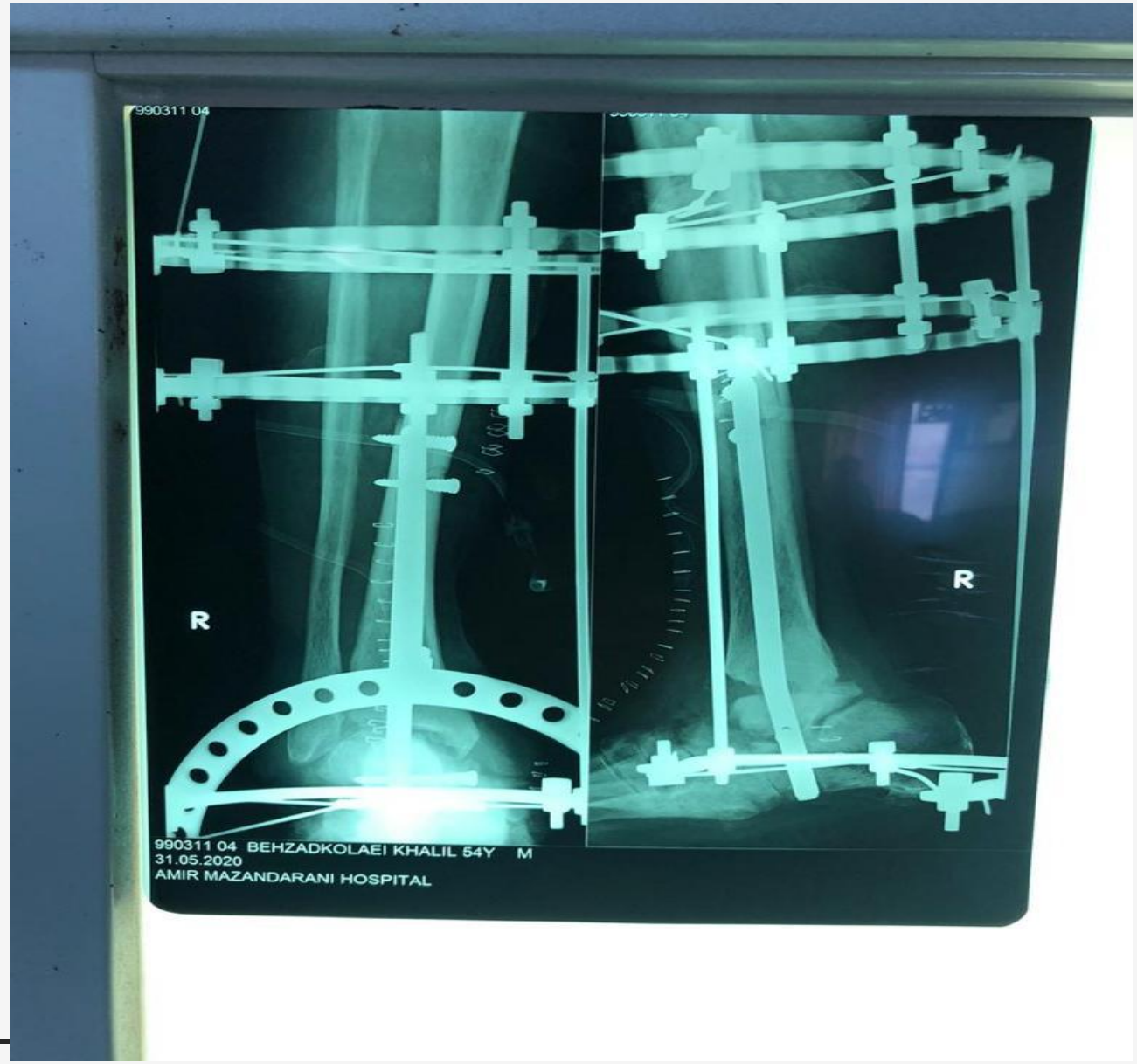
990311 04
R
R
990311 04 BEHZADKOLAEI KHALIL 54Y M
31.05.2020
AMIR MAZANDARANI HOSPITAL

Osteoporos Int (2013) 24:2729–2732
DOI 10.1007/s00198-013-2367-9

CASE REPORT

Successful treatment of nonunion with teriparatide after failed ankle arthrodesis for Charcot arthropathy

K. Tamai · K. Takamatsu · K. Kazuki

Received: 19 March 2013 / Accepted: 2 April 2013 / Published online: 7 May 2013
© The Author(s) 2013. This article is published with open access at Springerlink.com

Journal of Diabetes WILEY

ORIGINAL ARTICLE

Teriparatide (recombinant human parathyroid hormone [1-34]) increases foot bone remodeling in diabetic chronic Charcot neuroarthropathy: a randomized double-blind placebo-controlled study*

Ashu Rastogi[1†] | Abhishek Hajela[1†] | Mahesh Prakash[2] | Niranjan Khandelwal[2] | Rajender Kumar[3] | Anish Bhattacharya[3] | Bhagwant R. Mittal[3] | Anil Bhansali[1] | David G. Armstrong[4]