The Diabetic Foot

Dr.Hossein Farsavian

Epidemiology

- DM largest cause of neuropathy in N.A.
- Foot ulcerations is most common cause of hospital admissions for Diabetics
- Expensive to treat, may lead to amputation and
- need for chronic institutionalized care

Epidemiology

- $34,700/year (home care and social services) in amputee
- After amputation 30% lose other limb in 3 years
- After amputation 2/3^{rds} die in five years
- Type II can be worse
- 15% of diabetic will develop a foot ulcer

Aetiology of the Diabetic Foot

Neuropathy

Reduced response to infection

Ischaemia

Autonomic Neuropathy

Neuropathic Foot Changes

- Clawing/Retraction of minor digits
- Atrophy of plantar fatty pad
- Restricted ROM of joints
- Muscle wasting
- Warm feet
- Changes to joint alignment
- Skin anhydrosis

Charcot Arthropathy

- High Index of suspicion
- Diabetic
- Hot / red / swelling
- Trauma - minor / major
- Pain + / -
- Architectural Disruption
- Ulcer + / -

Hallett et al: Comprehensive Vascular and Endovascular Surgery © 2004 Elsevier Ltd.

Pressure Off-Loading

Total Contact Cast

Diabetic Air Walker

Aetiology of the Diabetic Foot

Neuropathy

Reduced response to infection

Ischaemia

Diabetic Foot Infection

Polymicrobial - gram (+) cocci, gram (-) bacilli and anaerobes

Redness and swelling may not be present

Suspect if deterioration in glycaemic control

Unusual foot pain with no fracture etc

Diabetic Foot Sepsis

Surgical principles

Drain pus urgently / immediately

Xray foot

Assess perfusion

Debride necrotic tissue

Revascularise early if required

MRI useful to assess soft tissues

Diabetic Foot Sepsis

Severe ischaemia is present in 5 to 15% of admitted cases of foot sepsis

Aetiology of the Diabetic Foot

Neuropathy

Reduced response to infection

Ischaemia

Diabetic Vascular Disease

Large vessel disease

- common
- early age of onset
- rapid progression

Microvascular disease

- presence in limbs controversial
- retinal and renal lesions common

Assessment of Foot Perfusion

Subjective

palpation of pulses

Objective

Doppler pressures (ankle/brachial index)

toe pressures

Management - Medical

↓ Progression of disease

Stop smoking

Rx predisposing factors

Foot care

Management - Medical

↓ progression of disease

↑ blood flow

Exercises

Drugs

-Antiplatelet :Aspirin / ticlopidine / clopidogrel

-Dipyridamole (Persantin)

-Pentoxiphylline (Trental)

-Cilostazol (Pletal)

Management - medical

↓ progression of disease

↑ blood flow

Relief of pain

-NSAIDS: check renal functions

-Opiates: cause constipation

-Epidural analgesia

-Antibiotic

-Drainage abscess

Management - intervention

Endovascular

- **Balloon angioplasty +/- Stent**

Surgery

- **Bypass**
  - **Anatomical**
    - **Aorto-bifemoral**
    - **Ileo-femoral**
    - **Femoro-popliteal**
  - **Extra-anatomical**
    - **Axillo-bifemoral**
    - **Femoro-femoral**

Case

52 yrs male

Smoking ++

DM X 5 yrs

Rest pain & blackening of right foot x 3 months

B\L lower limb pulses absent

ABI R - 0 , L – 0.2

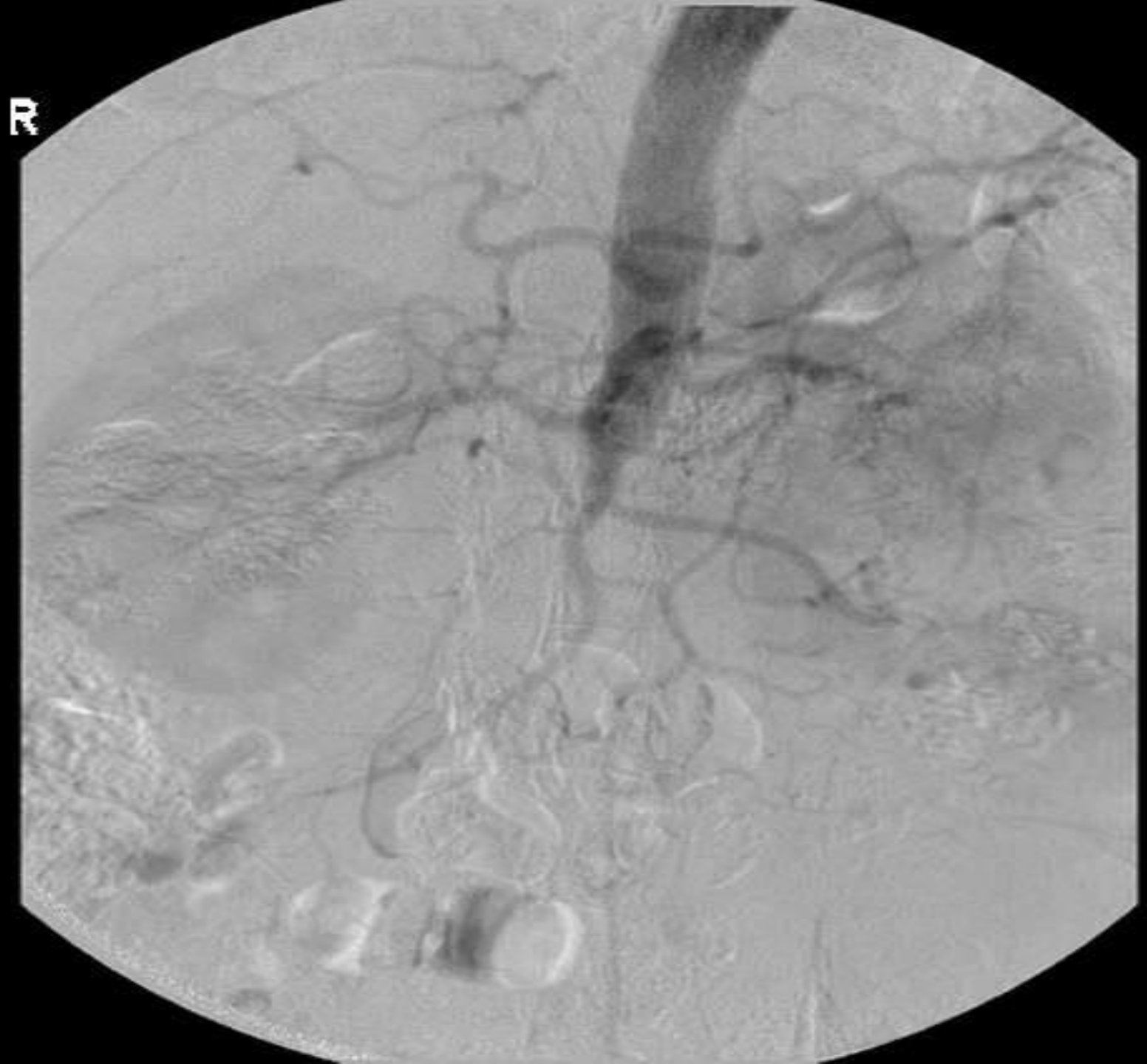
R

R

Management

Underwent emergency Aorto-bifem bypass and right trans-tarsal amputation

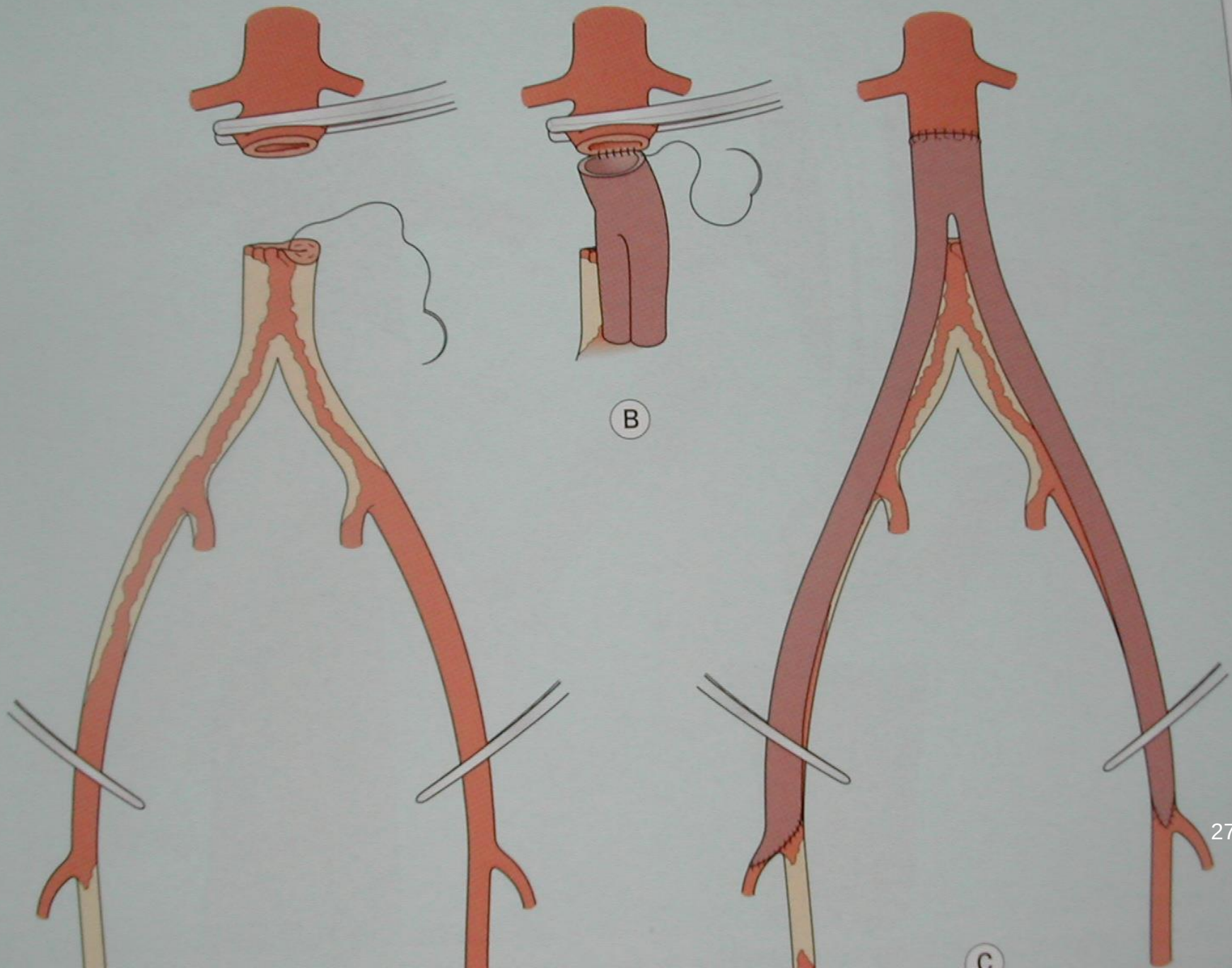
B
C

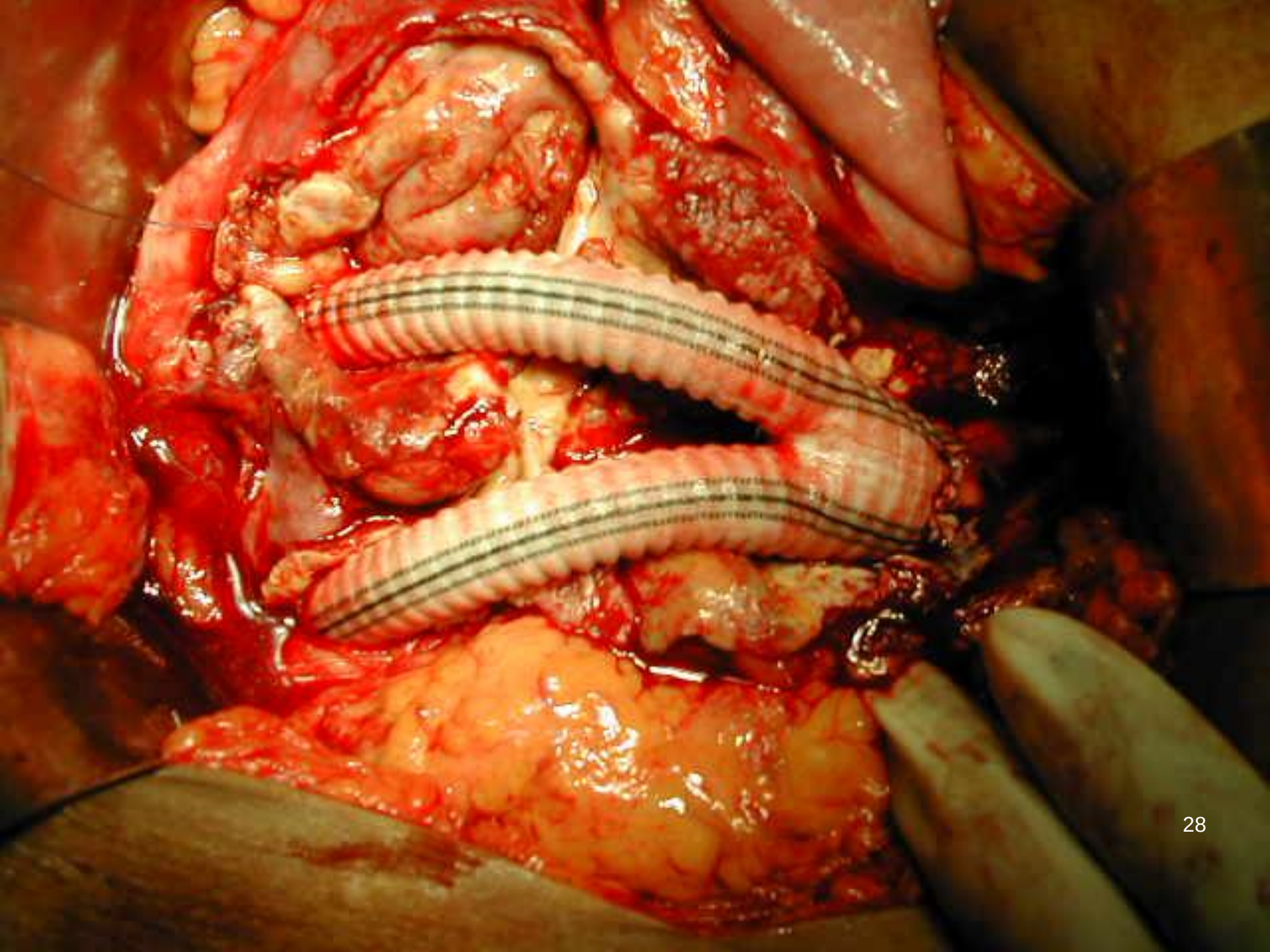

Outcome

Post Op ABI left 1.1

Right stump healed well

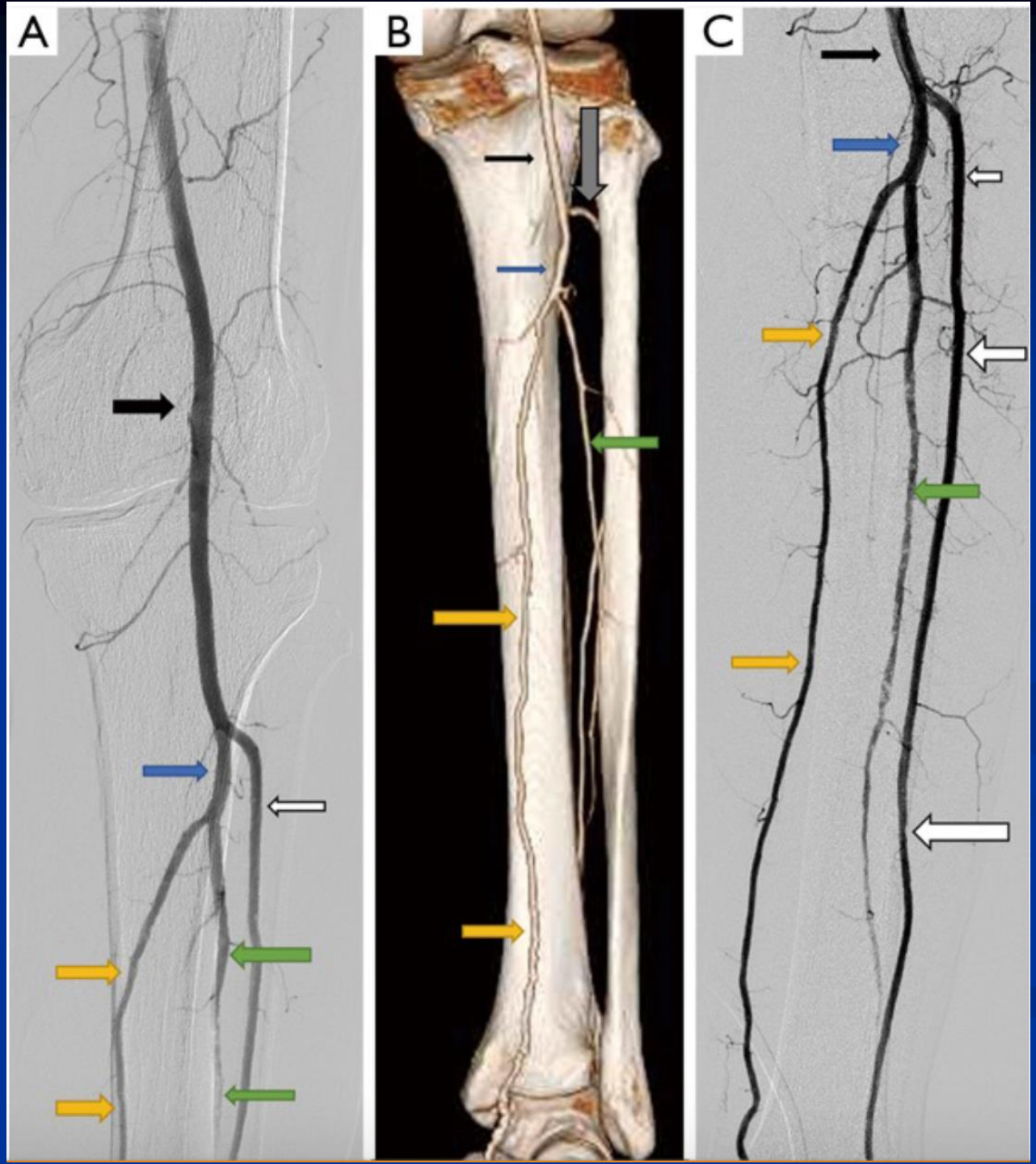
A
B
C

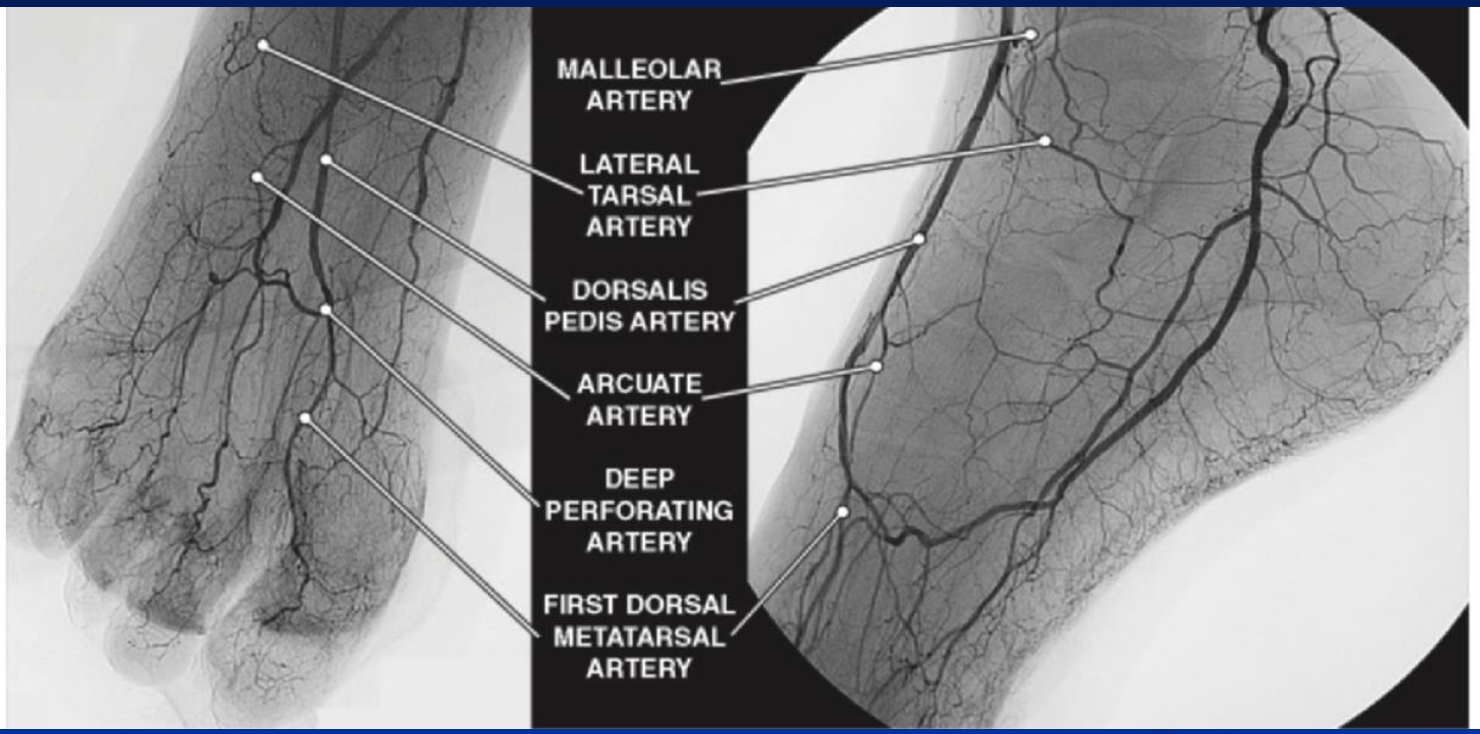
MALLEOLAR ARTERY
LATERAL TARSAL ARTERY
DORSALIS PEDIS ARTERY
ARCUATE ARTERY
DEEP PERFORATING ARTERY
FIRST DORSAL METATARSAL ARTERY

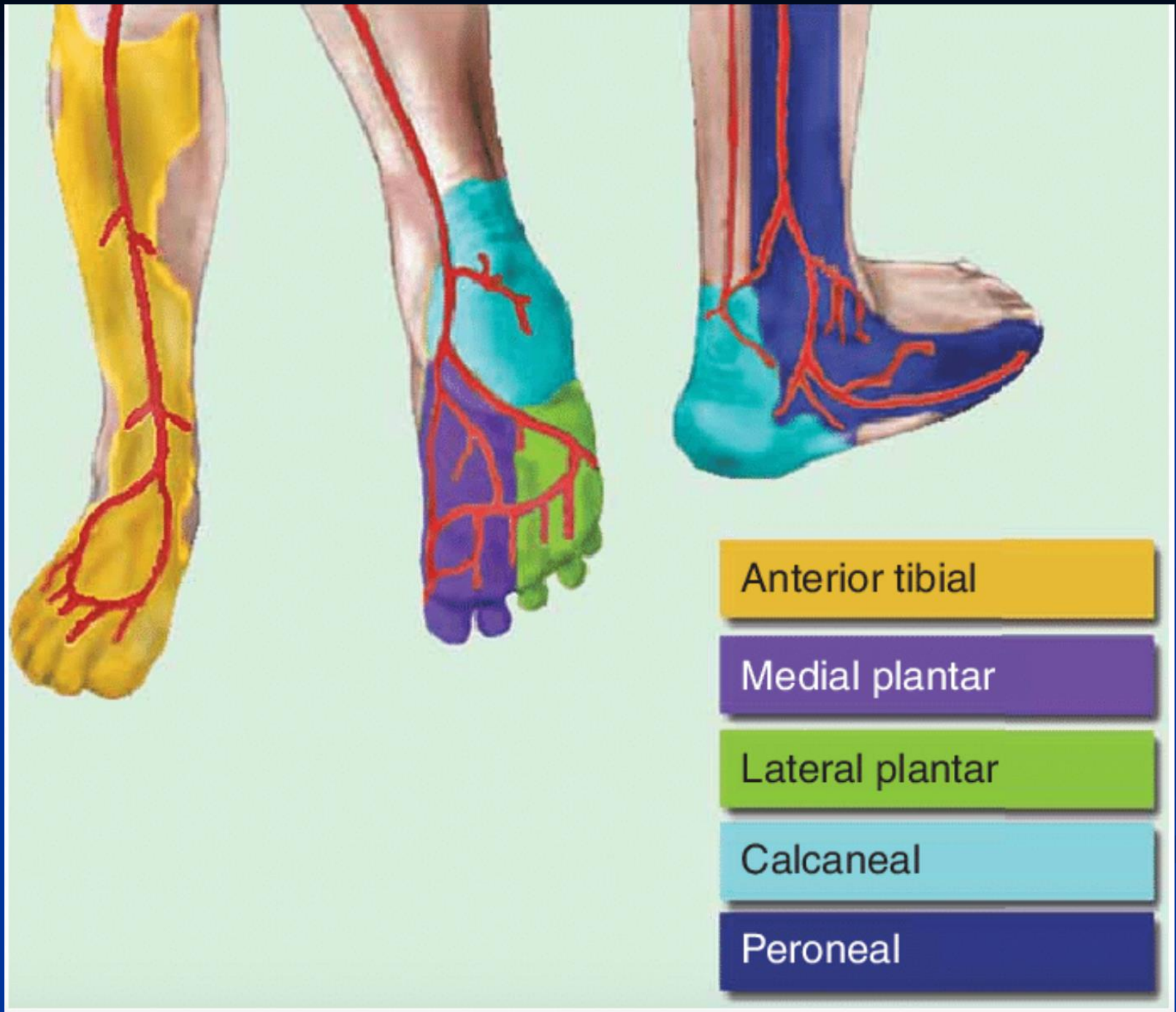
Anterior tibial
Medial plantar
Lateral plantar
Calcaneal
Peroneal

b.

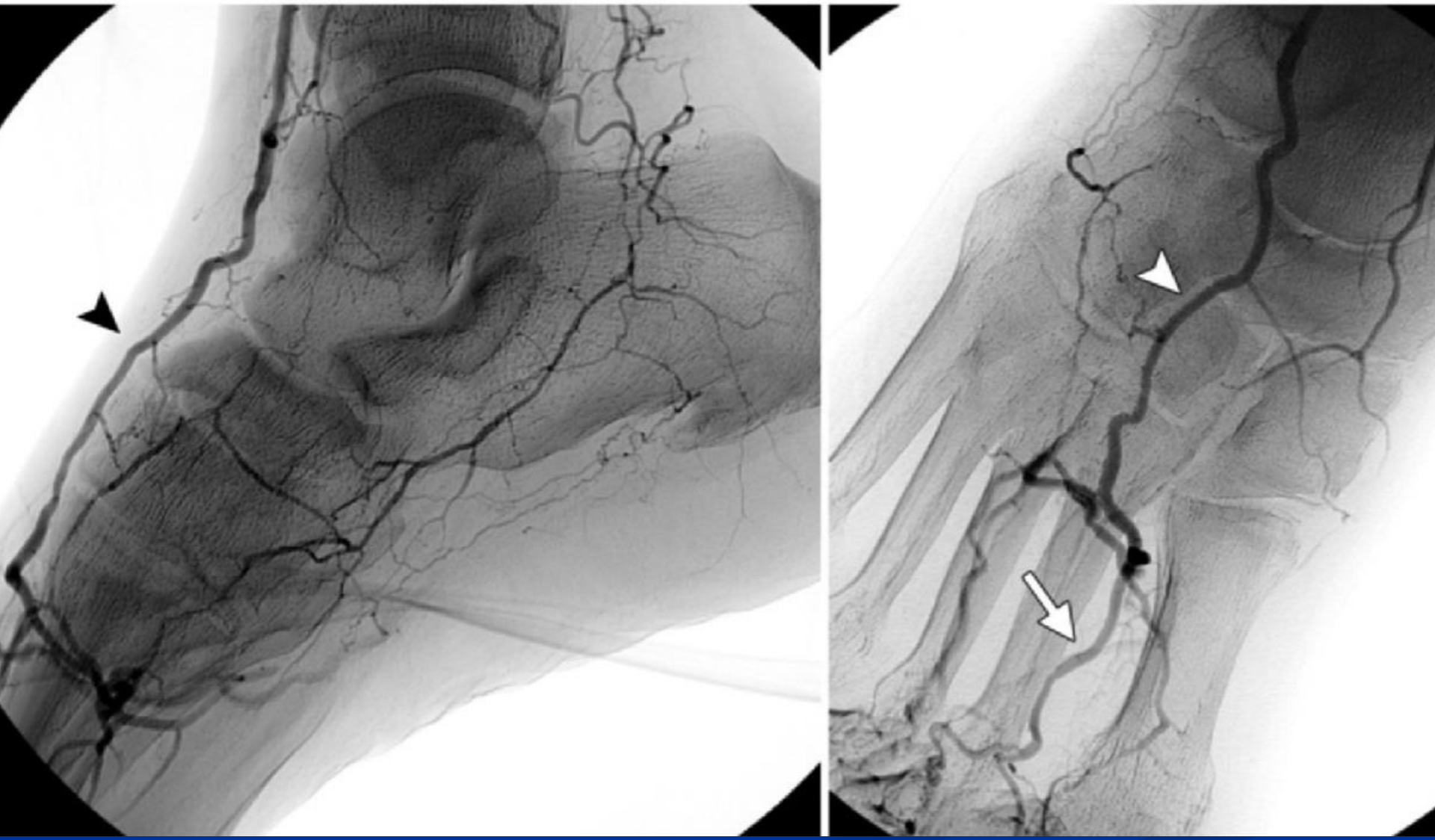

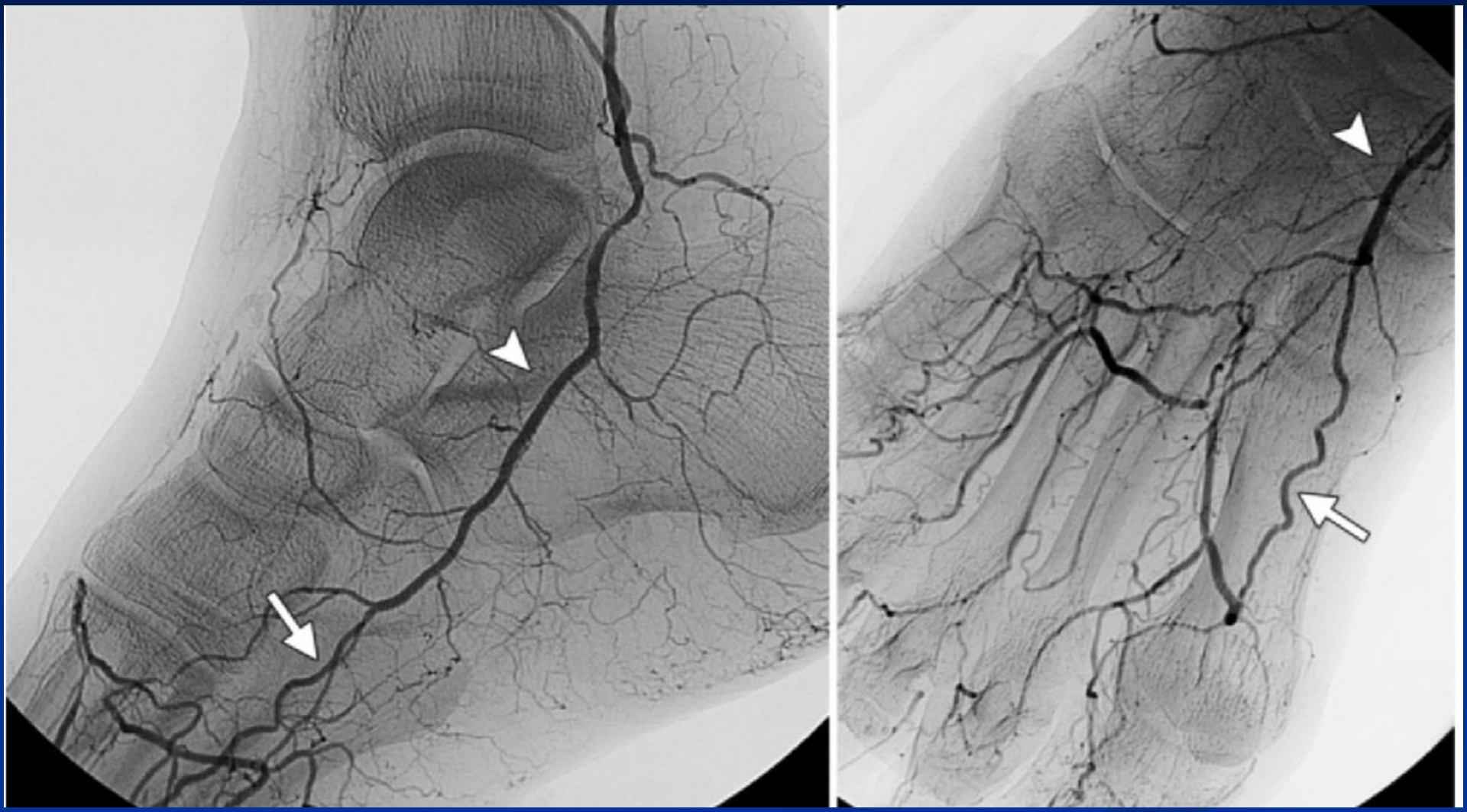

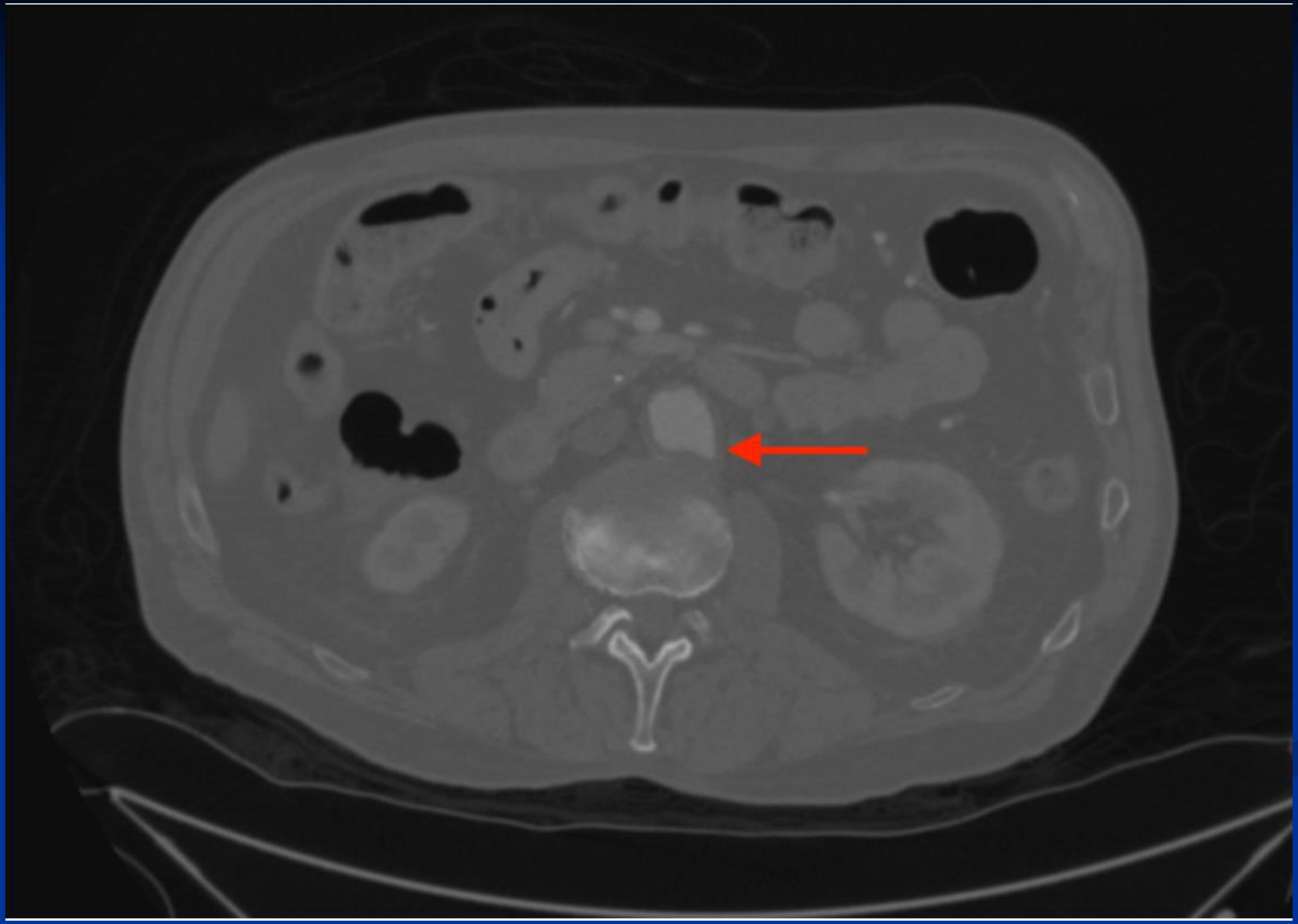

Second case

DR **Hossein Farsavian**
Vascular Surgeon in University Hospital
Mazandaran University of Medical Science

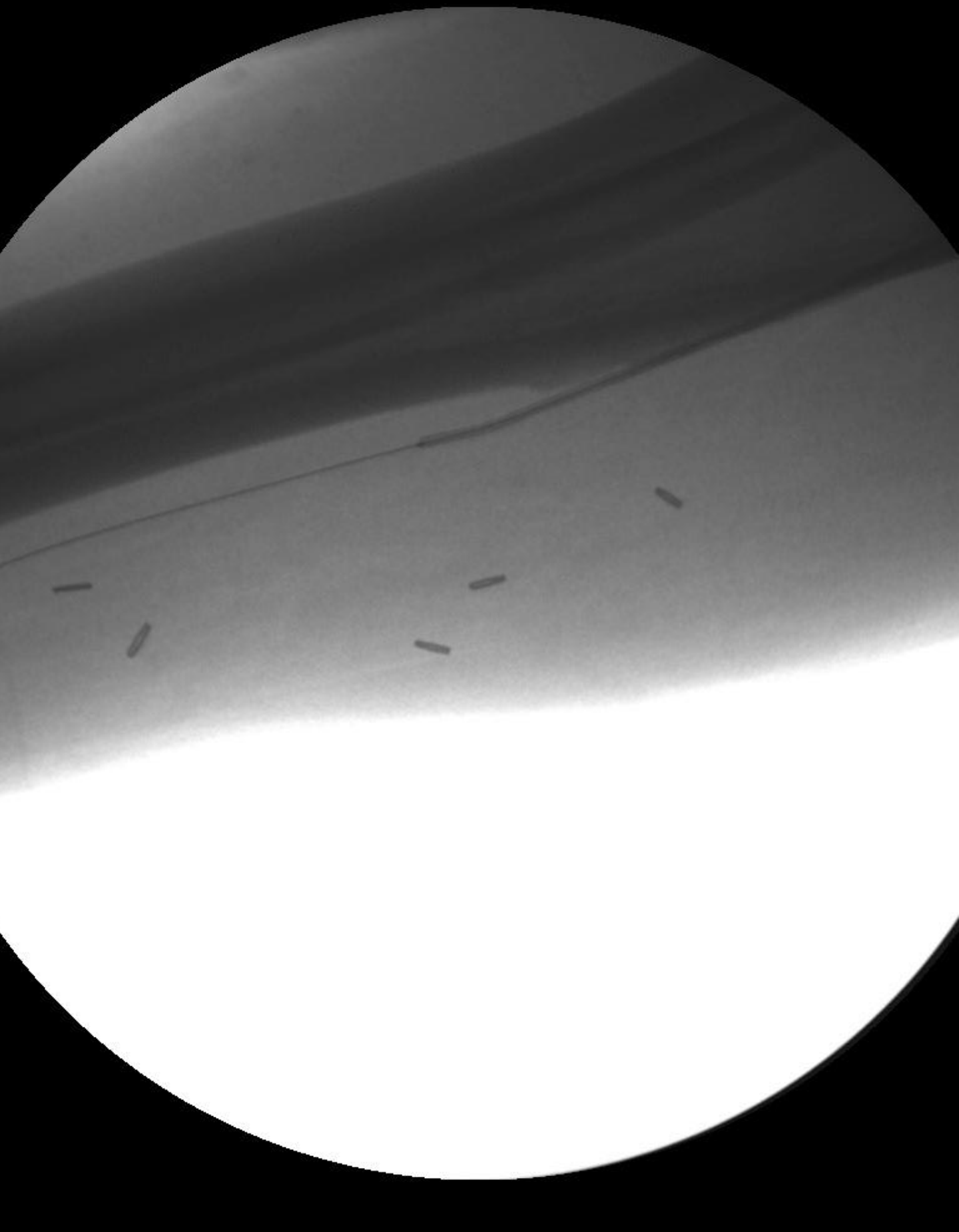

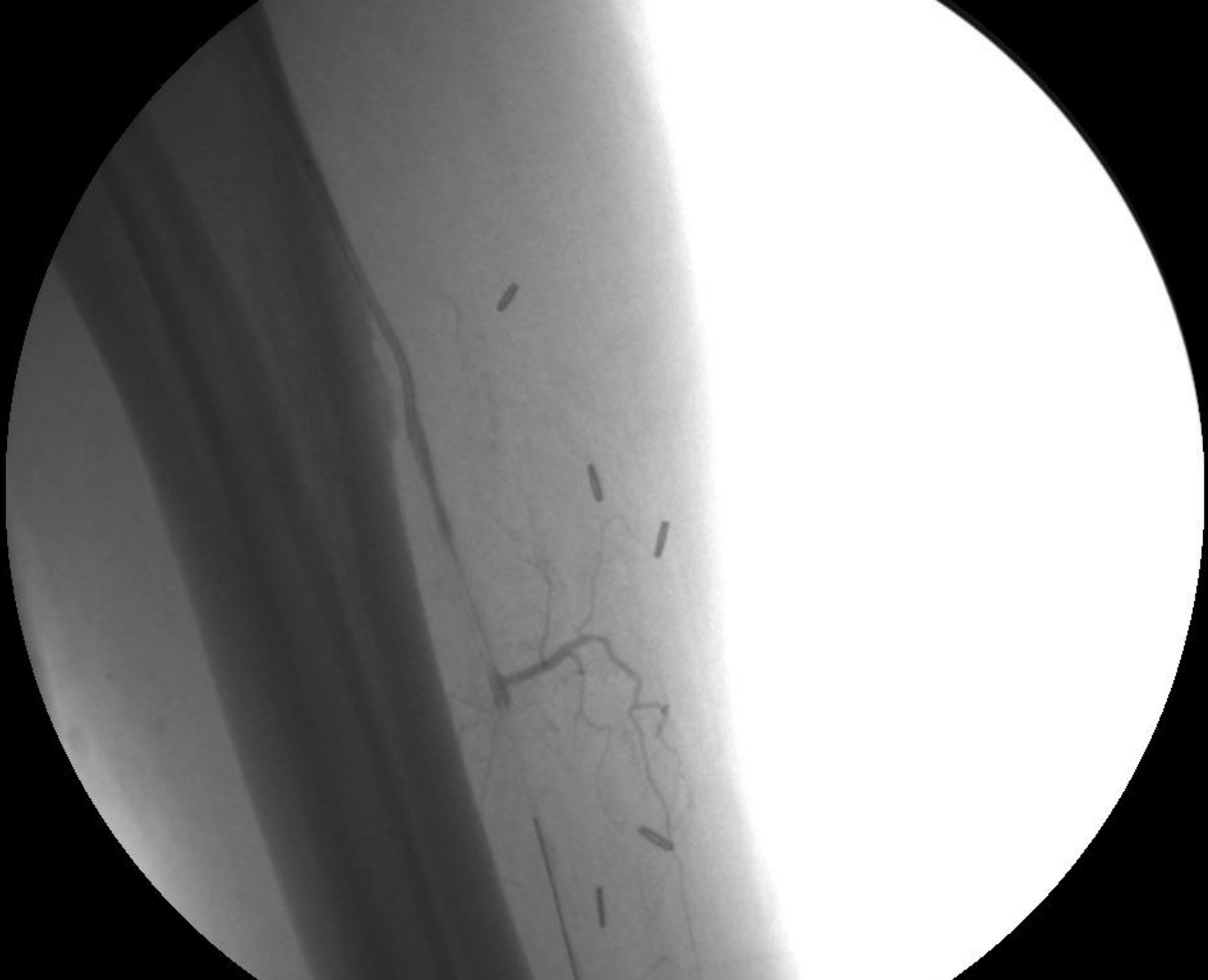

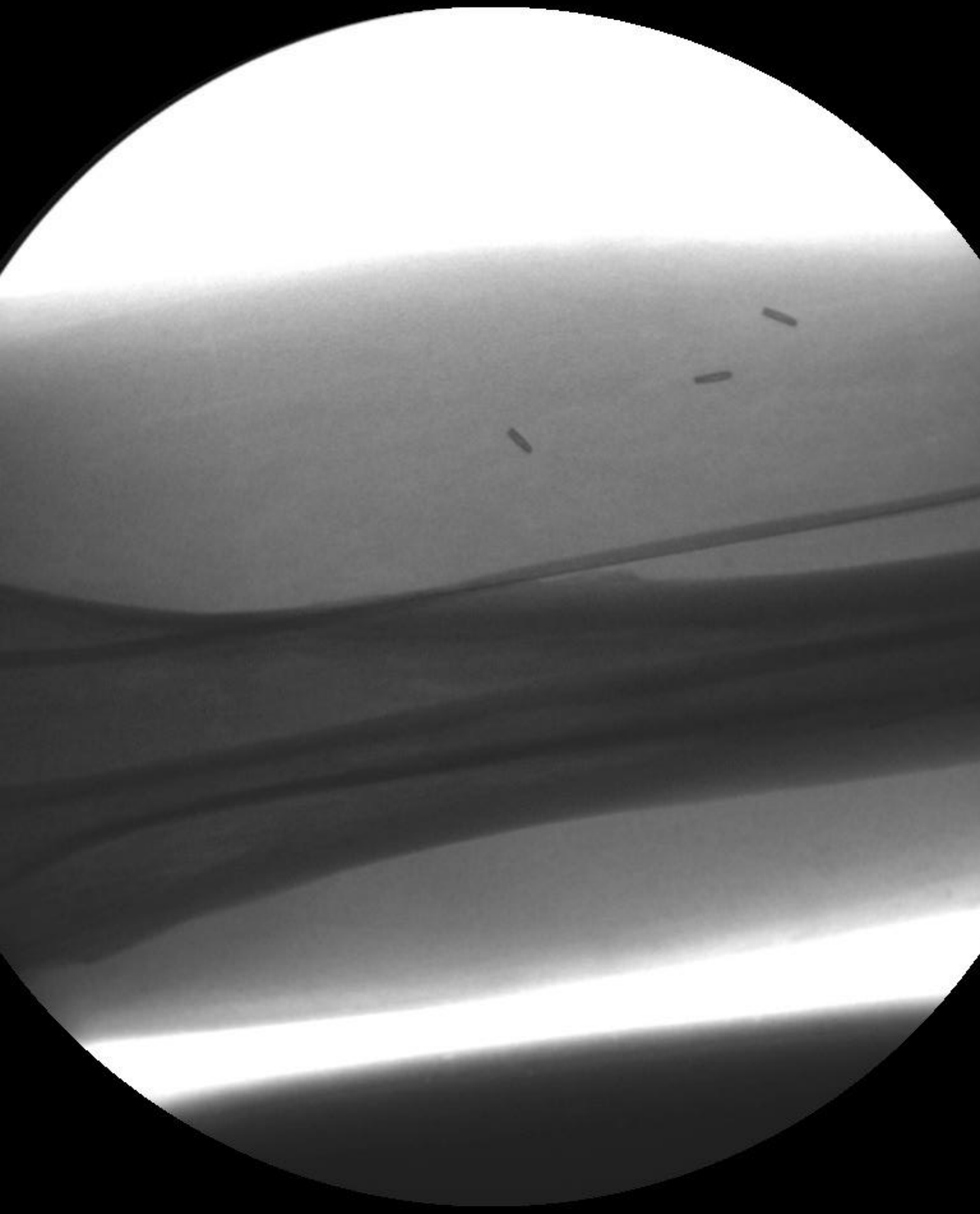

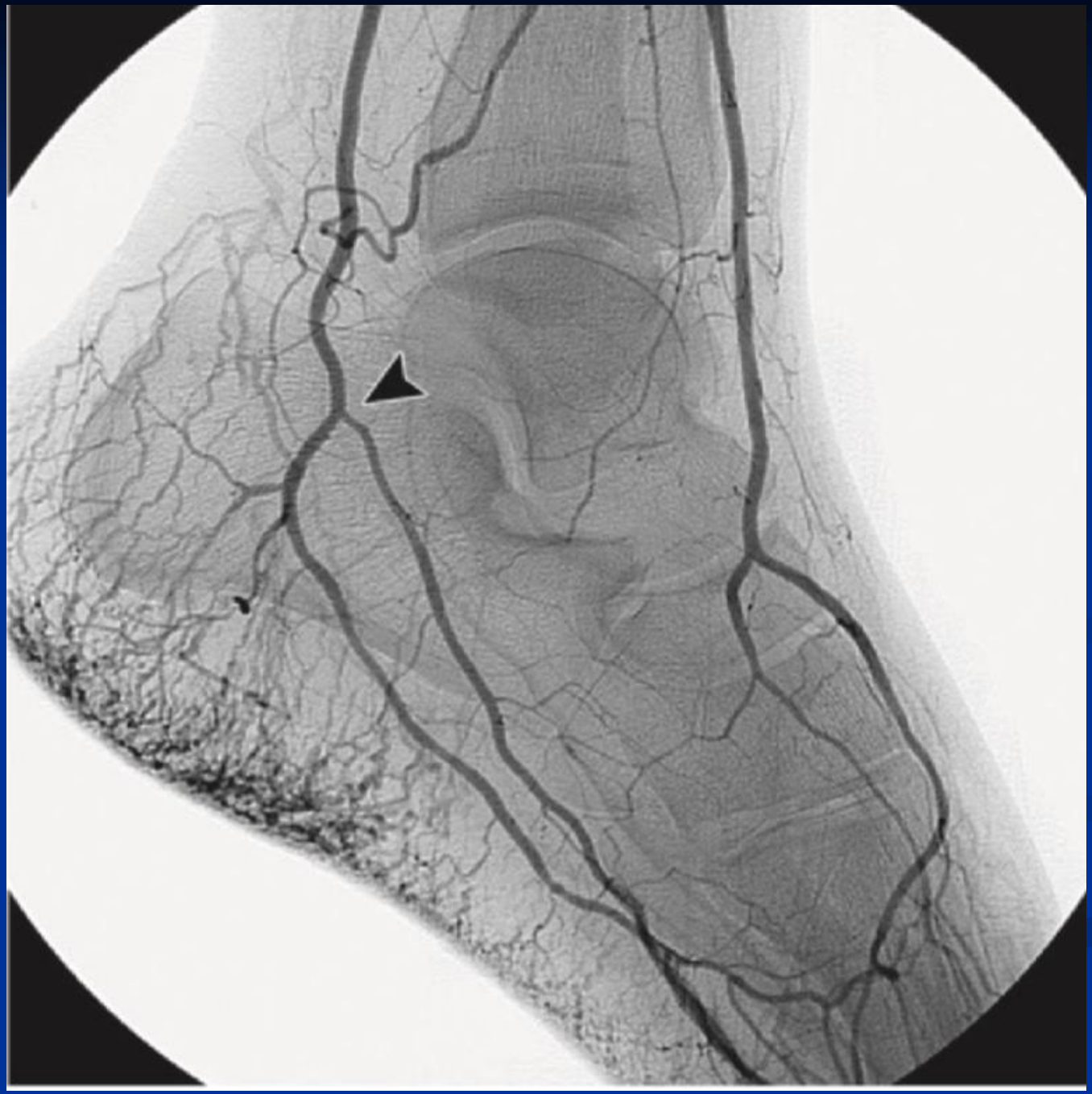
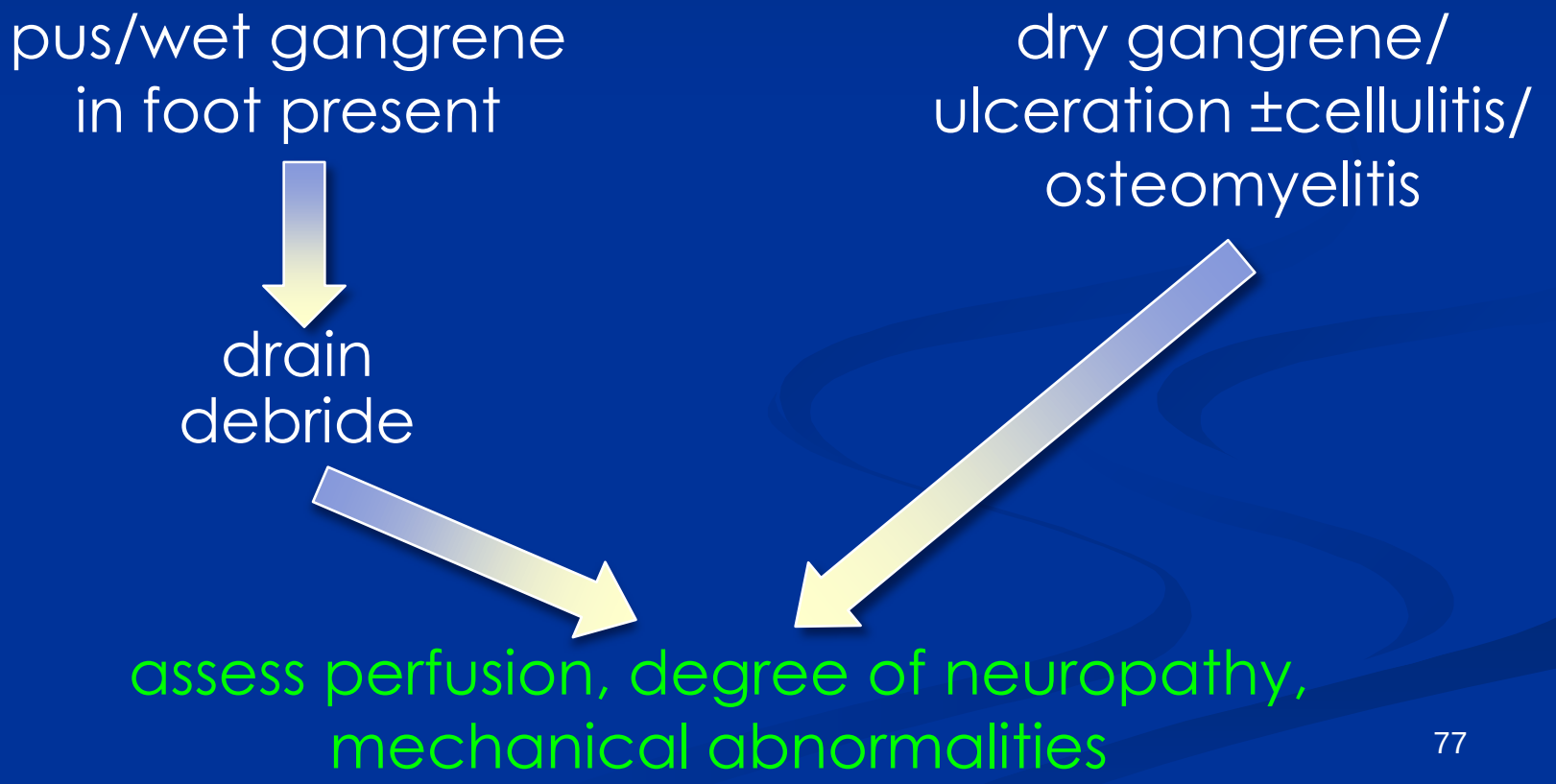
Management Algorithm for th Diabetic Foot Lesion